

Introductory course – gynecology

Tiril Tingleff, Rikshospitalet
tiril.tingleff@medisin.uio.no

“Feminine linjer” (“Feminine lines”) by Harald Kryvi

Gynecological exam - Indications



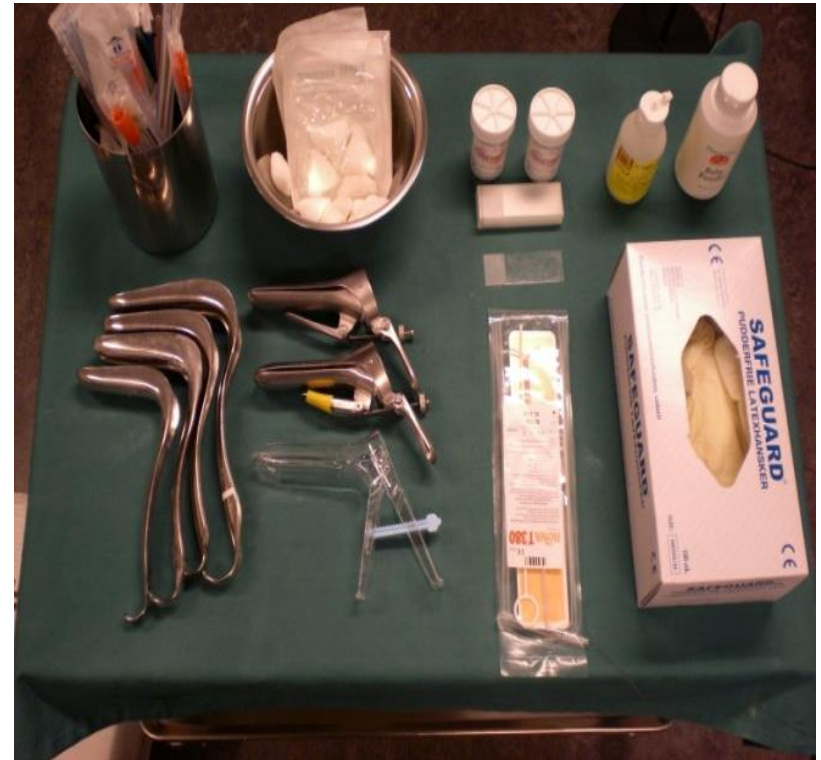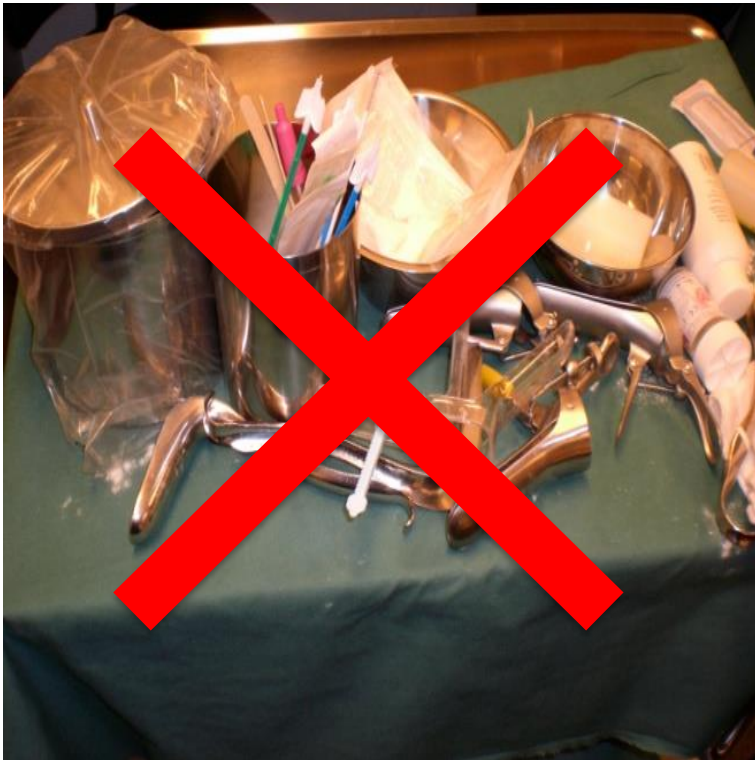Indications

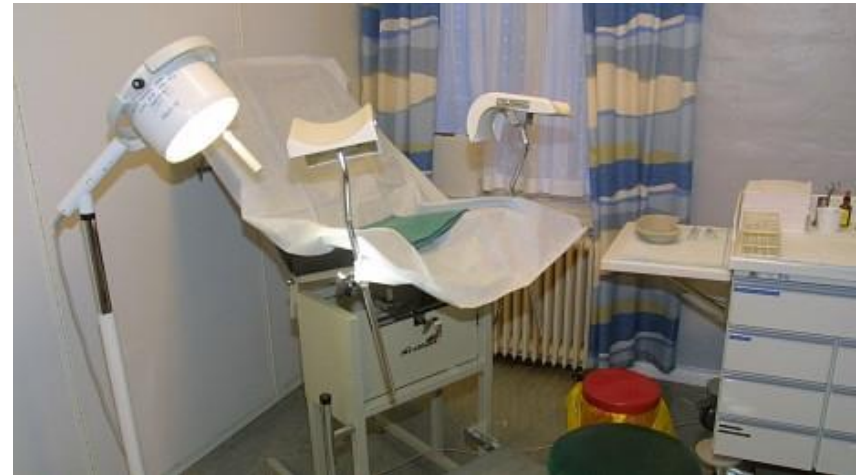- Abdominal pain
 - Abnormal bleeding
 - menstrual problems, intermenstrual-, postcoital-, postmenopausal bleeding
 - Screening of cervical precancer
 - Vaginal/vulvar discomfort
 - abnormal discharge, pain, itching, wounds, blisters, masses
 - Sexually transmitted infections
 - Pregnancy?
- ++

Gynecological history taking

- Menstrual history
 - menarche, cycle interval and length, pain, volume
- Contraception
- Previous gynecological history
- Cervical screening
 - NB! Any previous abnormal cytology findings?
- History of pregnancies and deliveries/parity
- Sexual function
- Menopause, use of HRT (hormonal replacement therapy)
- Vulvar, vaginal or abdominal symptoms

The examination table





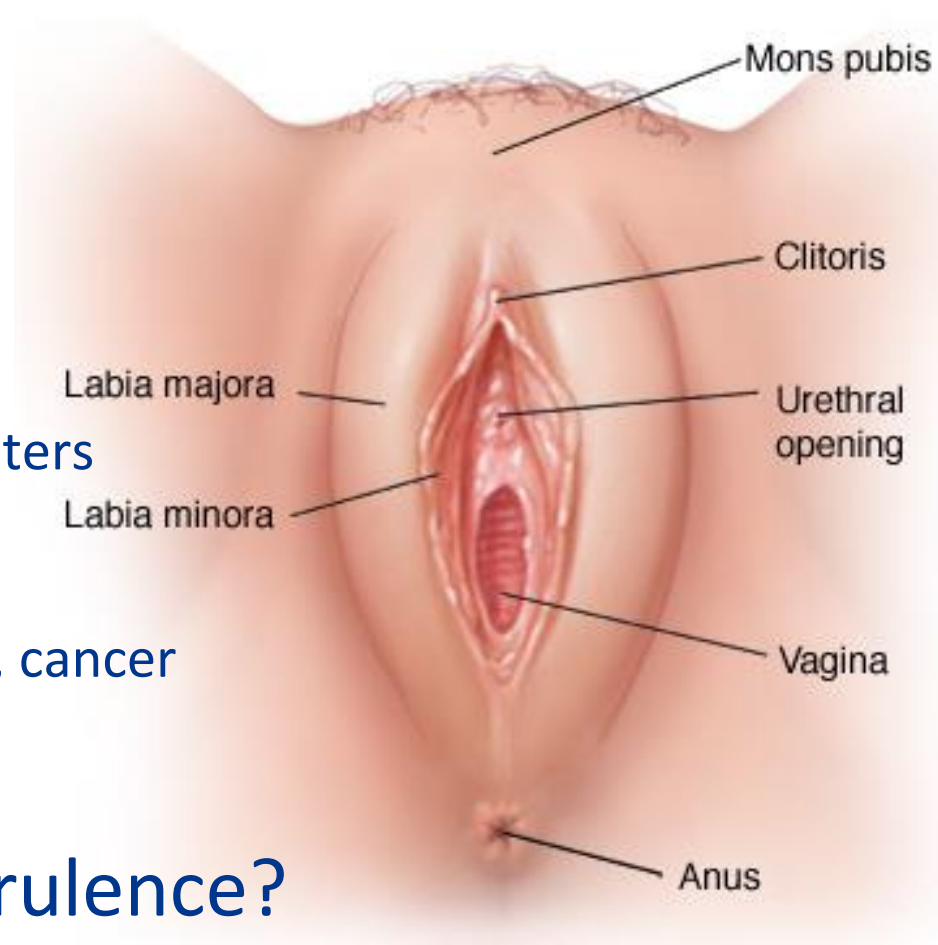


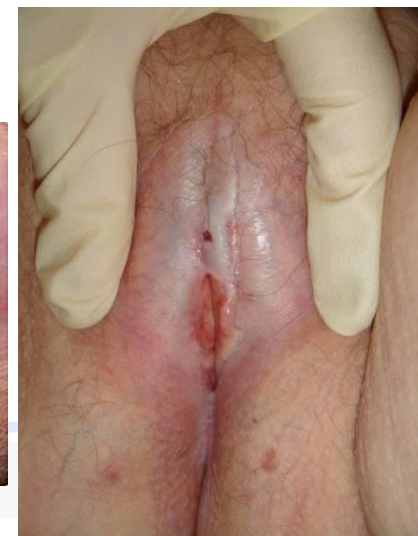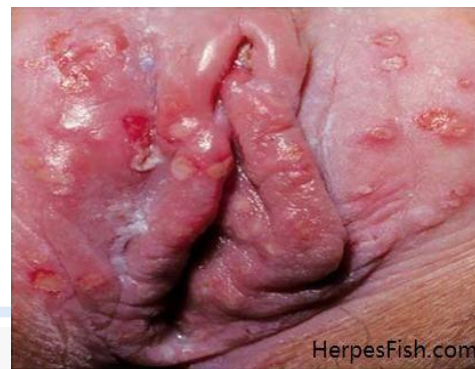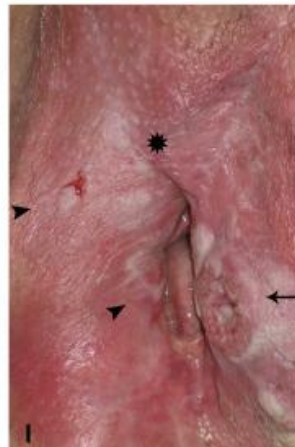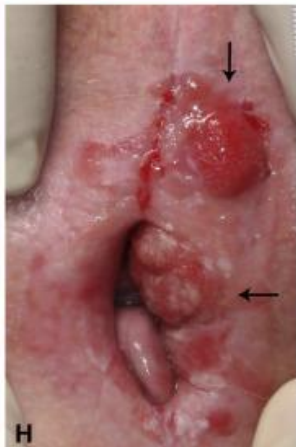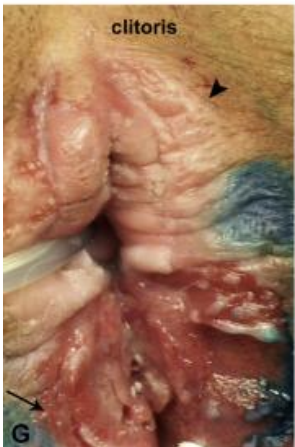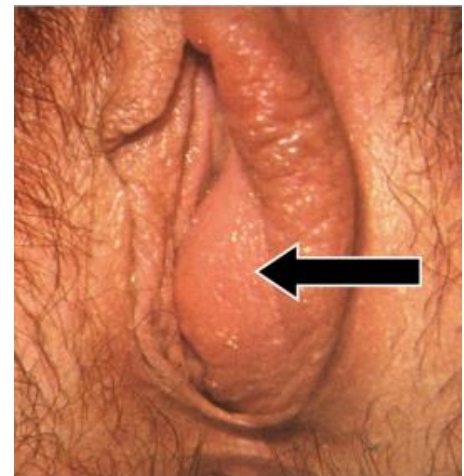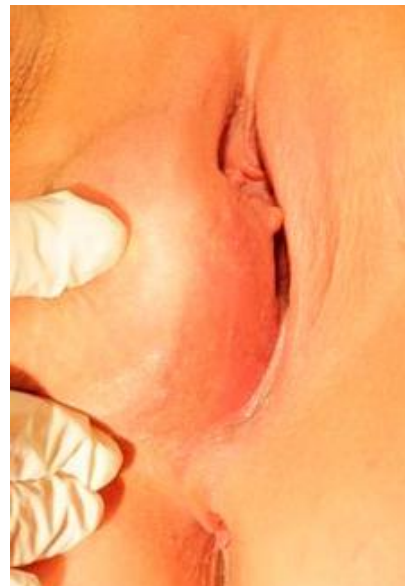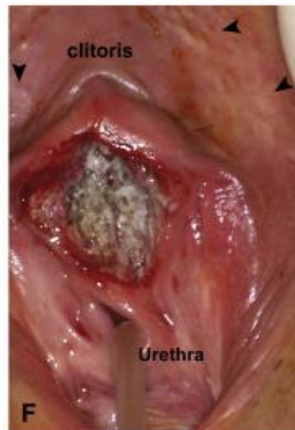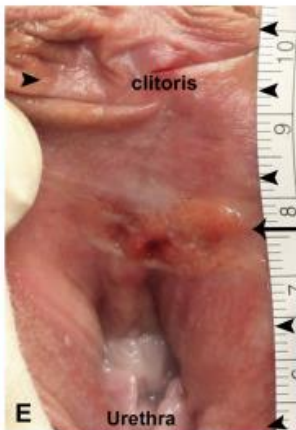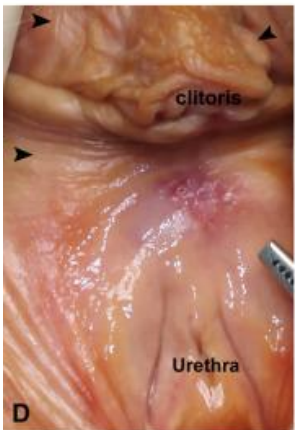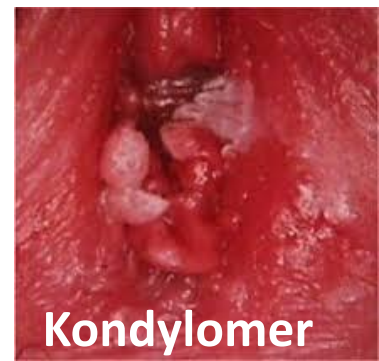
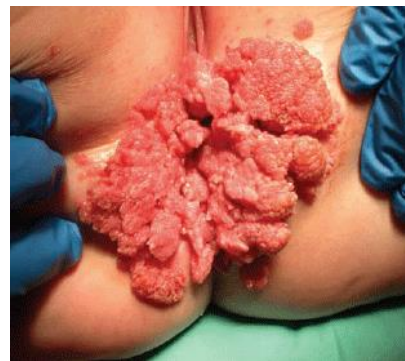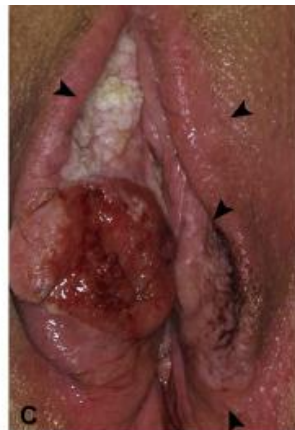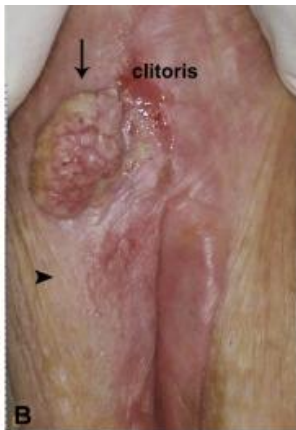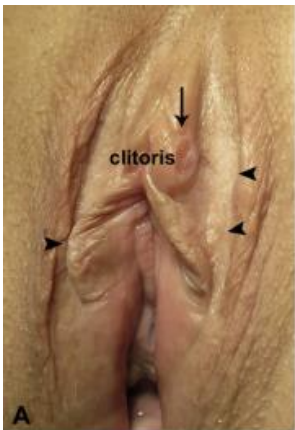What do we examine?

«Det spøker bak vesica urinaria»
(«A haunted urinary bladder») by Harald Kryvi

Inspection of the vulva

- Anatomy
- Skin
 - colour/skin changes
- Lesions
 - fissures, wounds, scars, blisters
- Tumours
 - condylomas, abscess, cysts, cancer
- Pubic hair
- Discharge/blood/purulence?

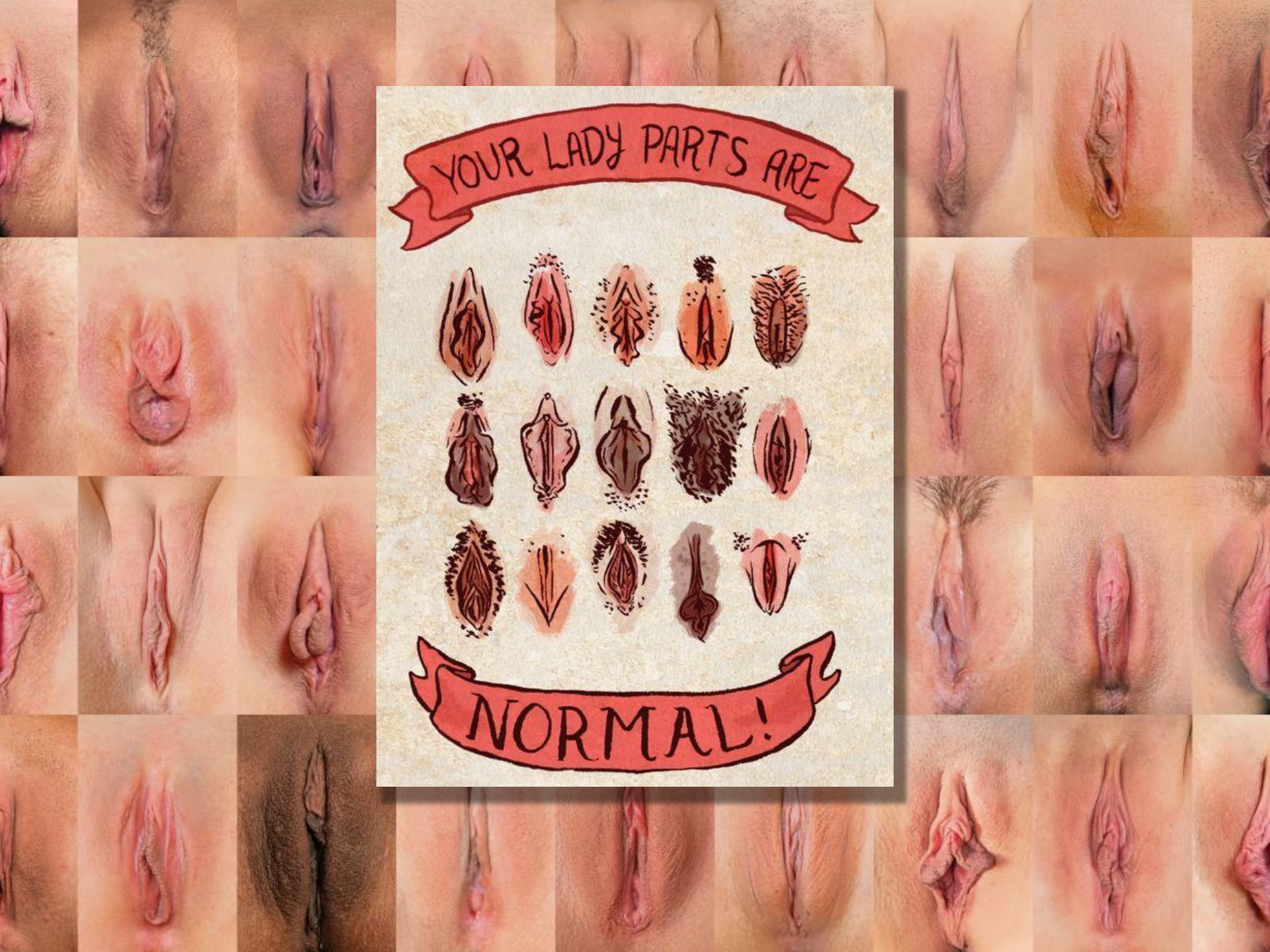



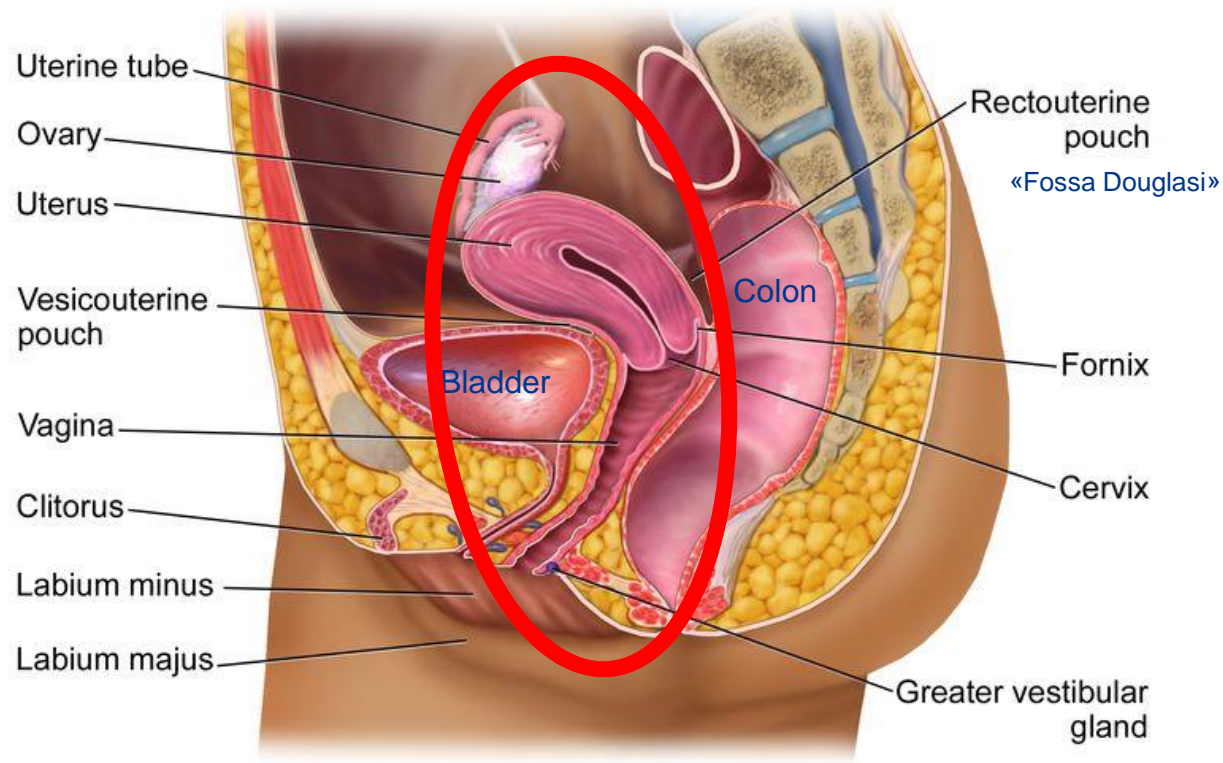
YOUR LADY PARTS ARE



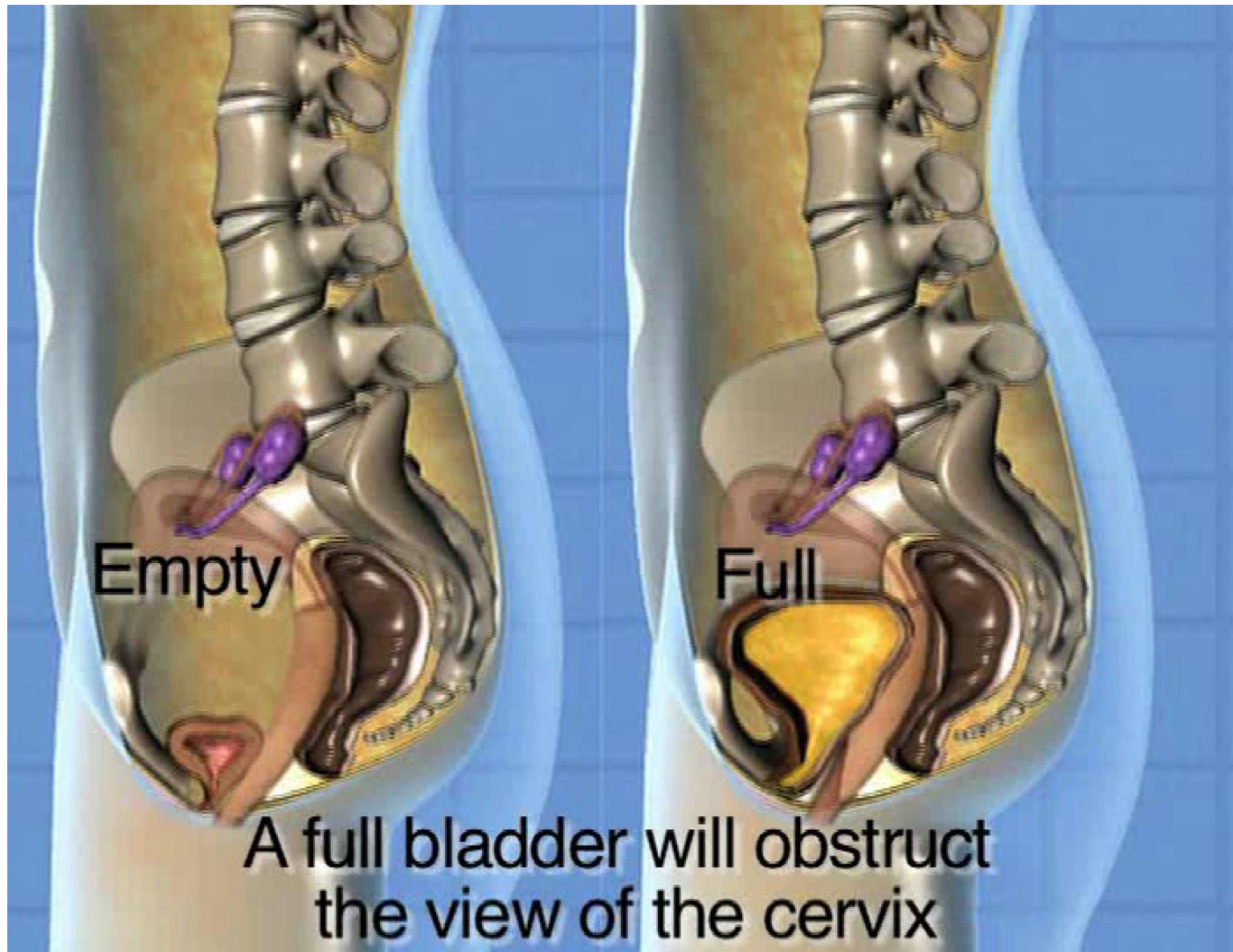
NORMAL!



The vagina, cervix and uterus



The Female Reproductive System



Inspection

Use of *speculum* to inspect the vagina and the portio/cervix

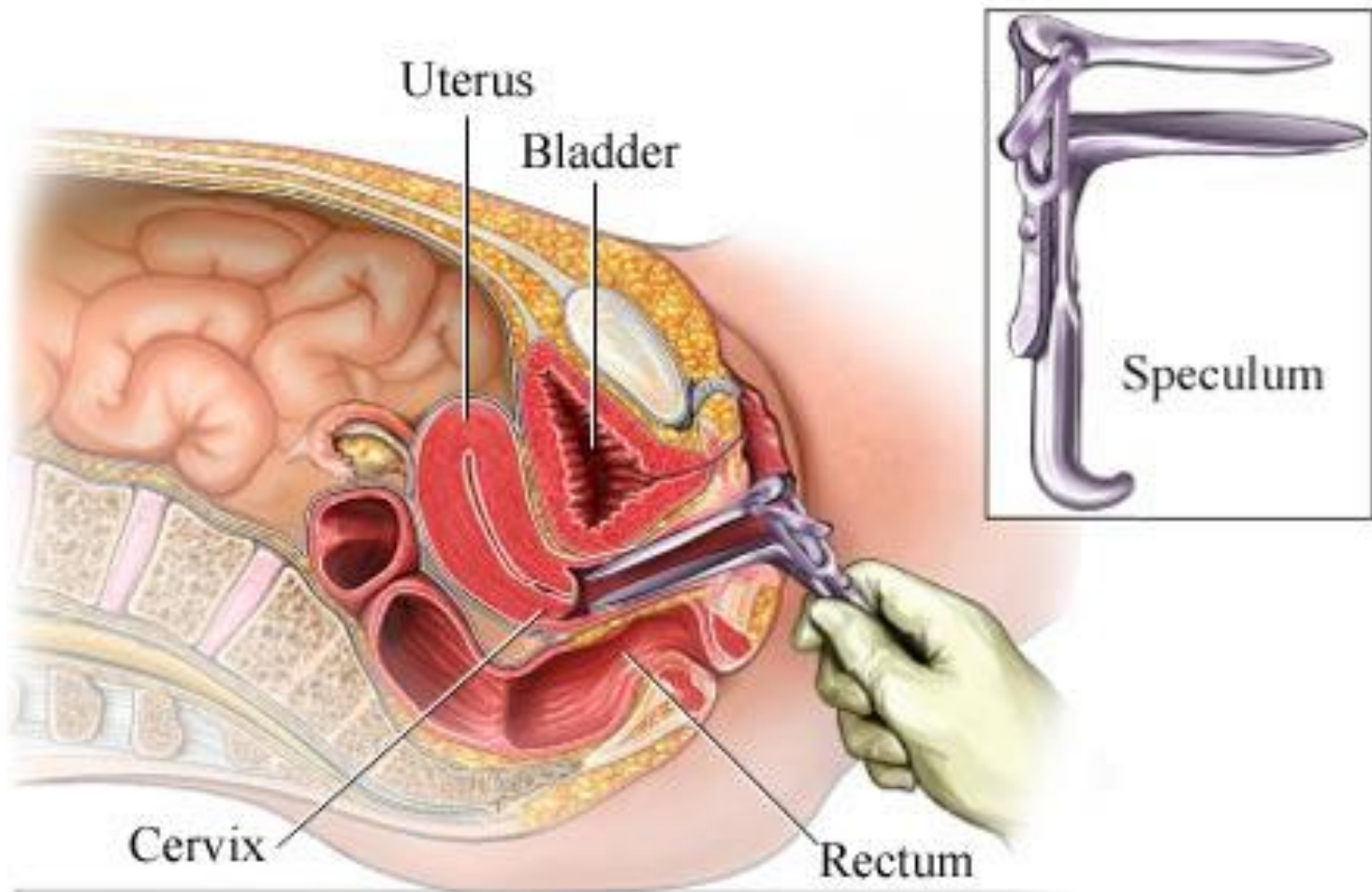
Cuscos' / "self-retaining"



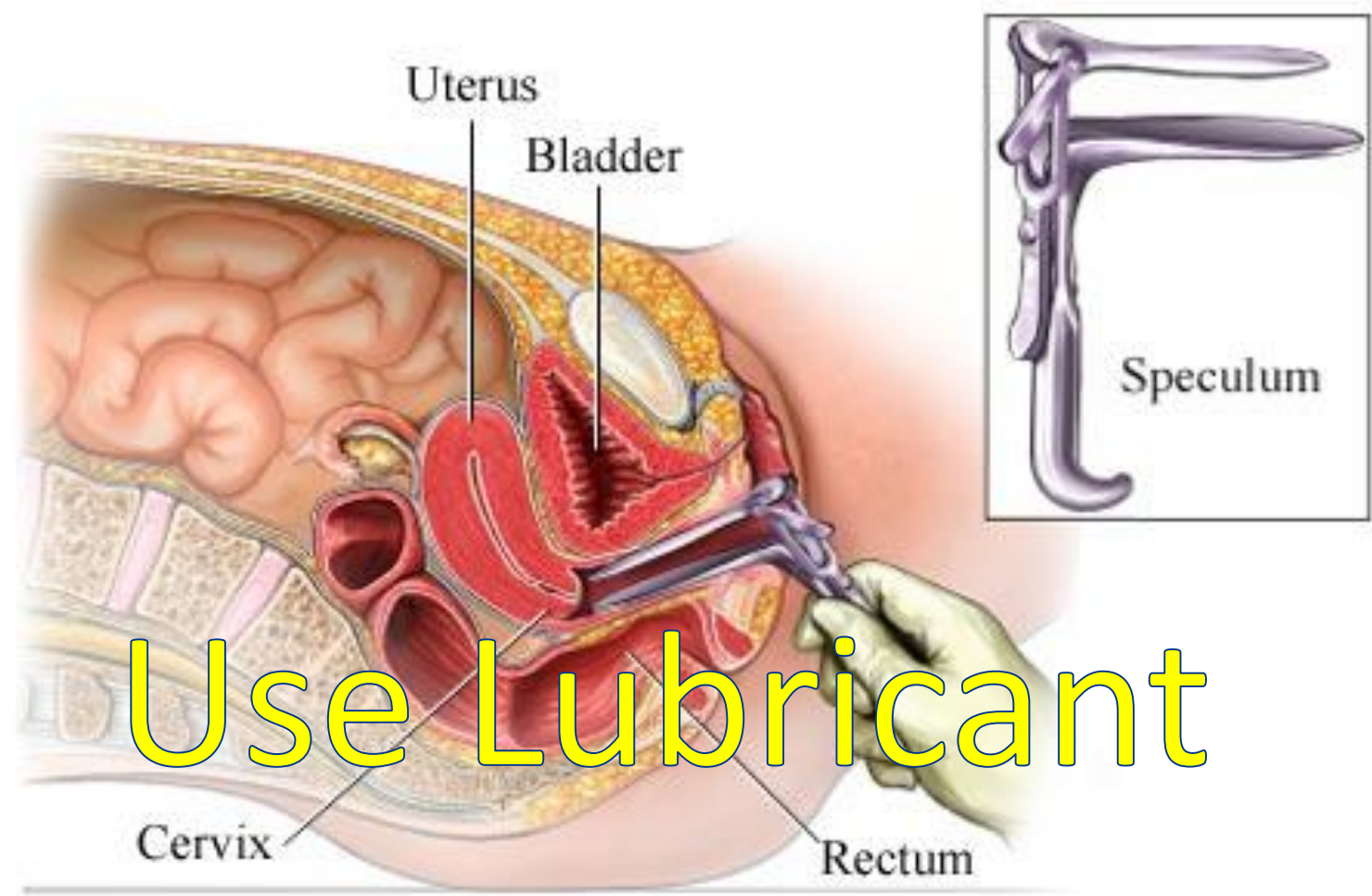
Sims



The speculum examination

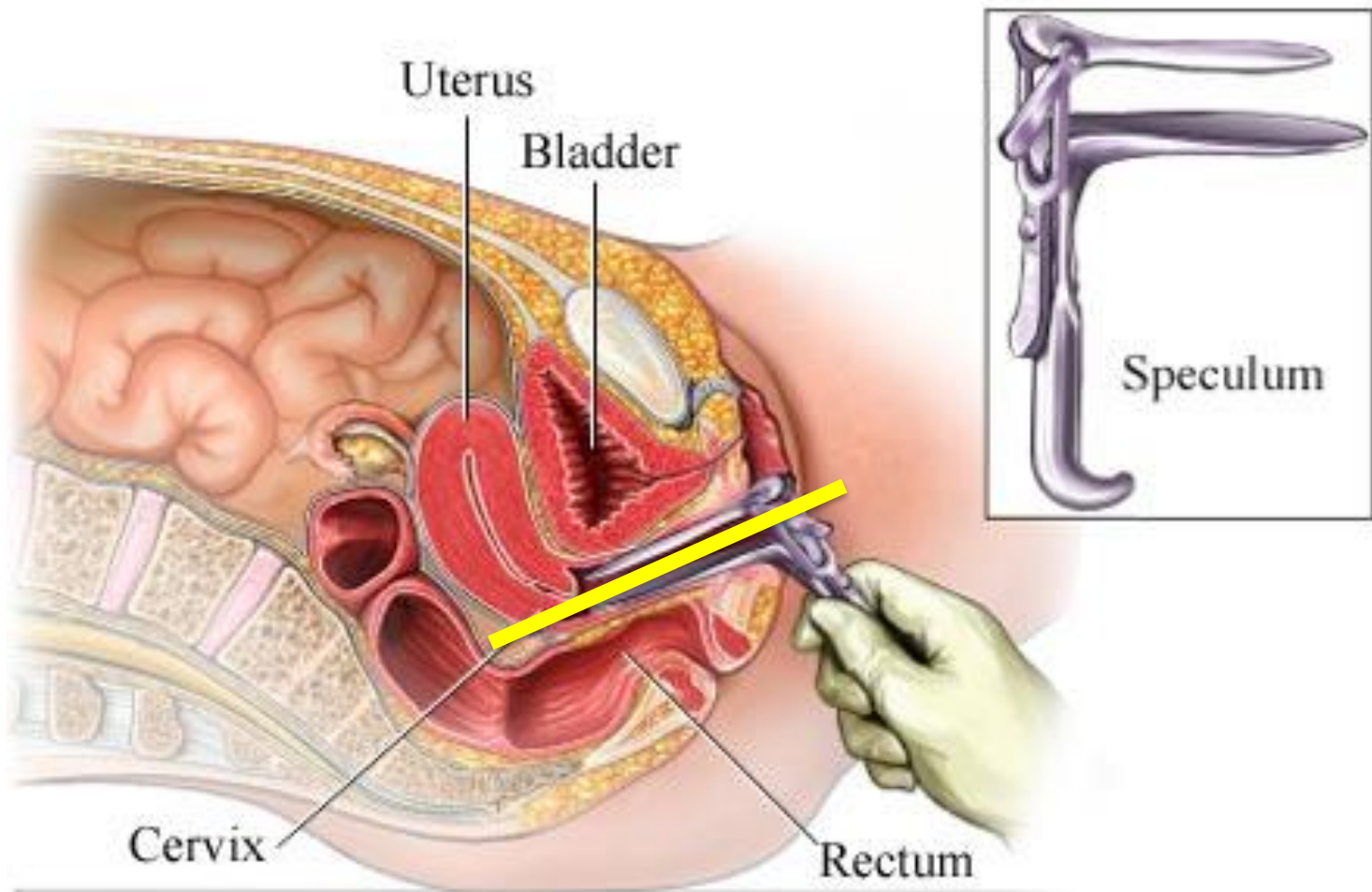


The speculum examination



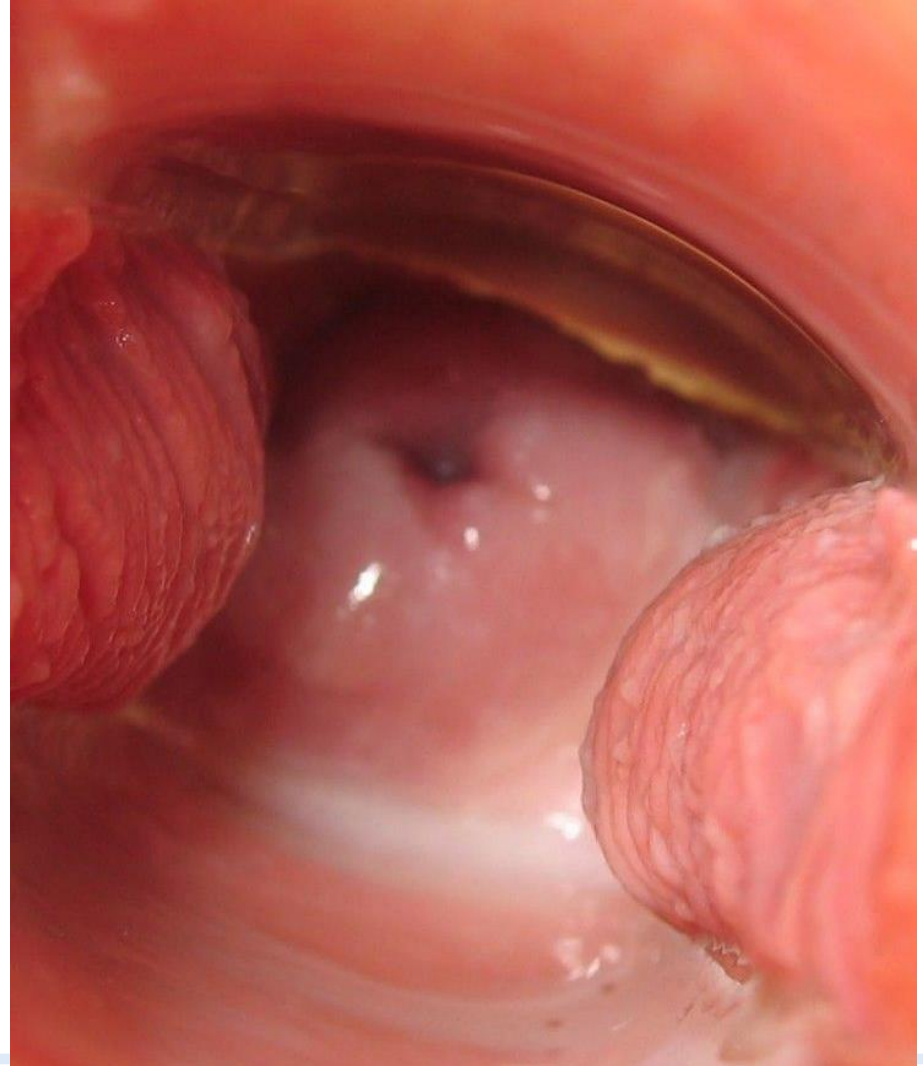
Use Lubricant

Remember - the "angle"!

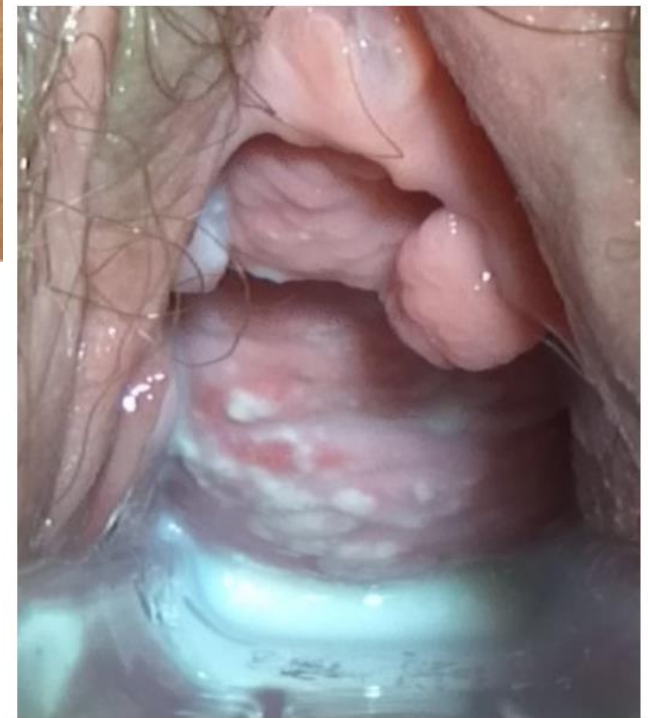
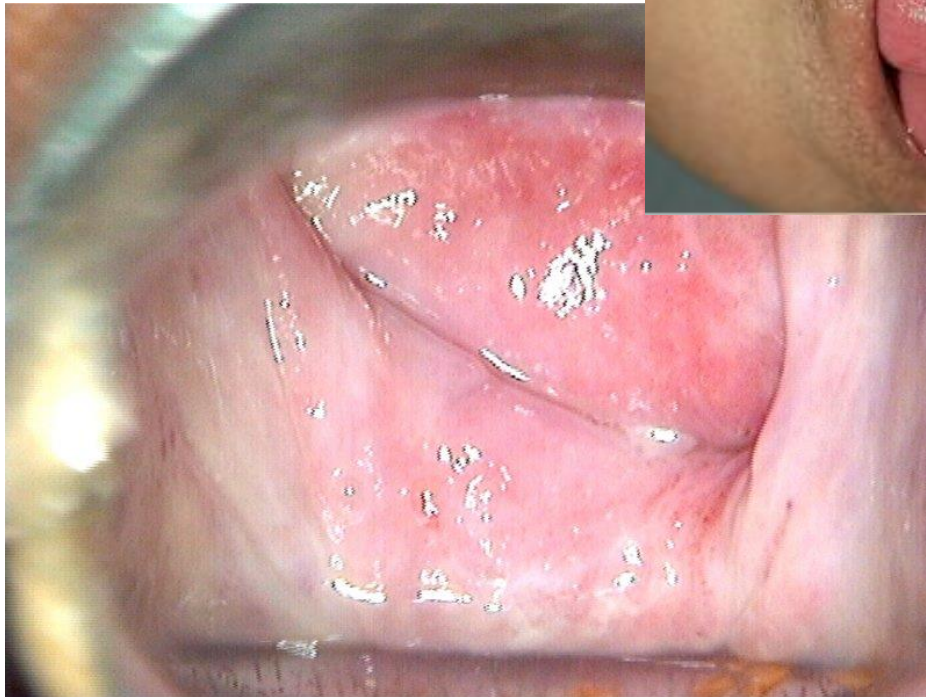
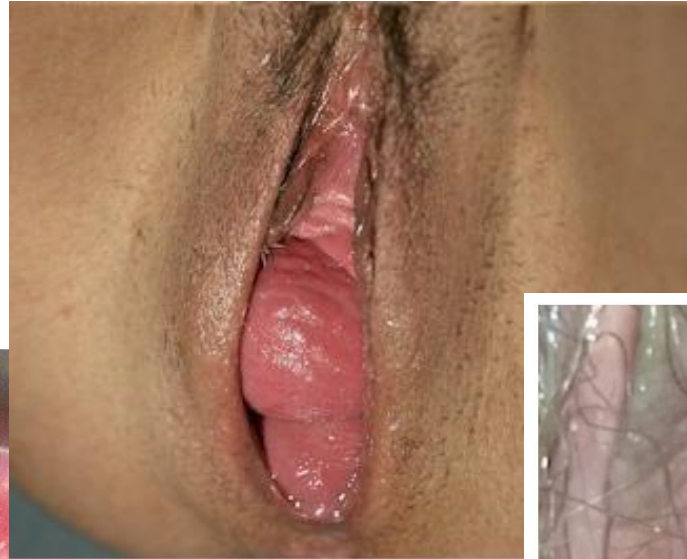Inspection of the vagina

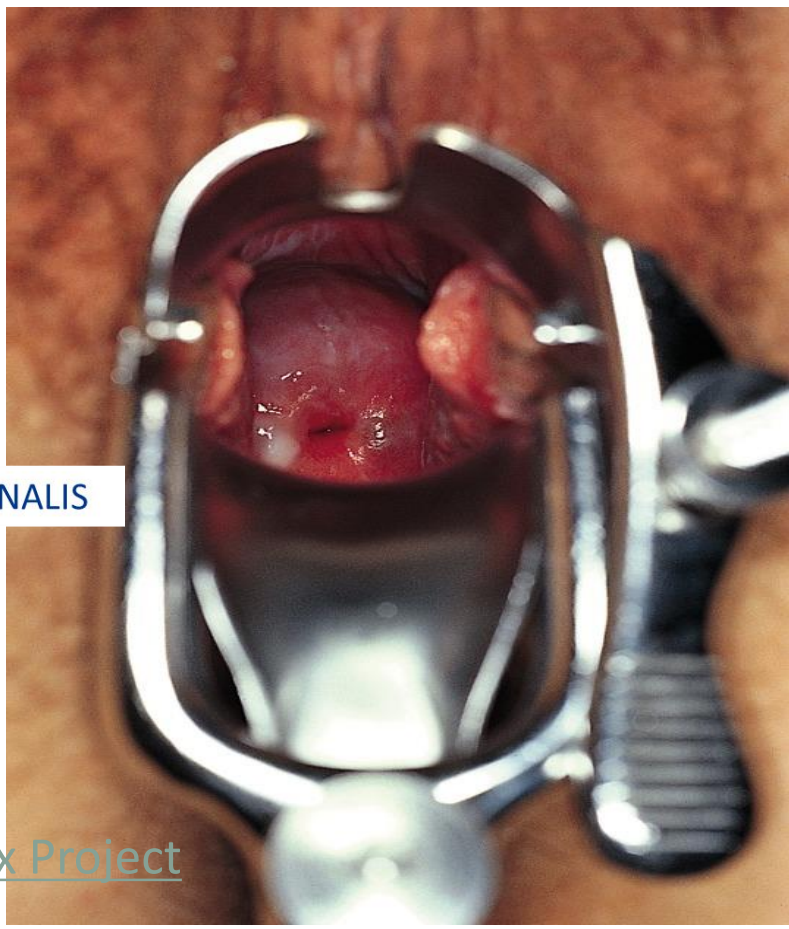
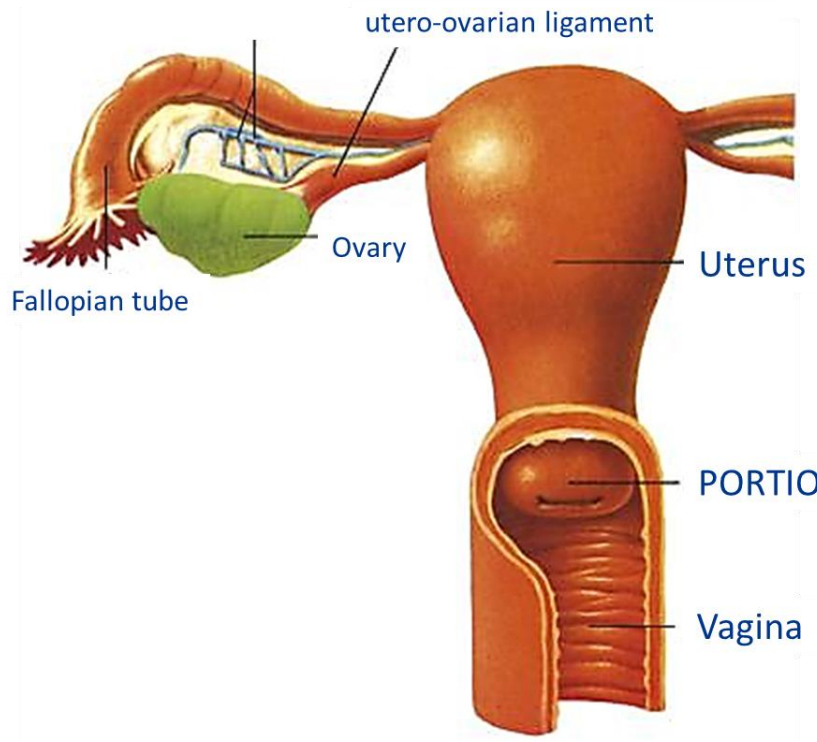
- Anatomy/shape
 - Prolapse?
- Colour
 - Pink, pale, red?
- Estrogenization
 - Rugae? Moist/dry?
- Blood?
- Discharge
- Lesions?
 - Fissures, wounds?
- Tumores?
 - Condylomas, cysts, cancer?



Inspection of the vagina

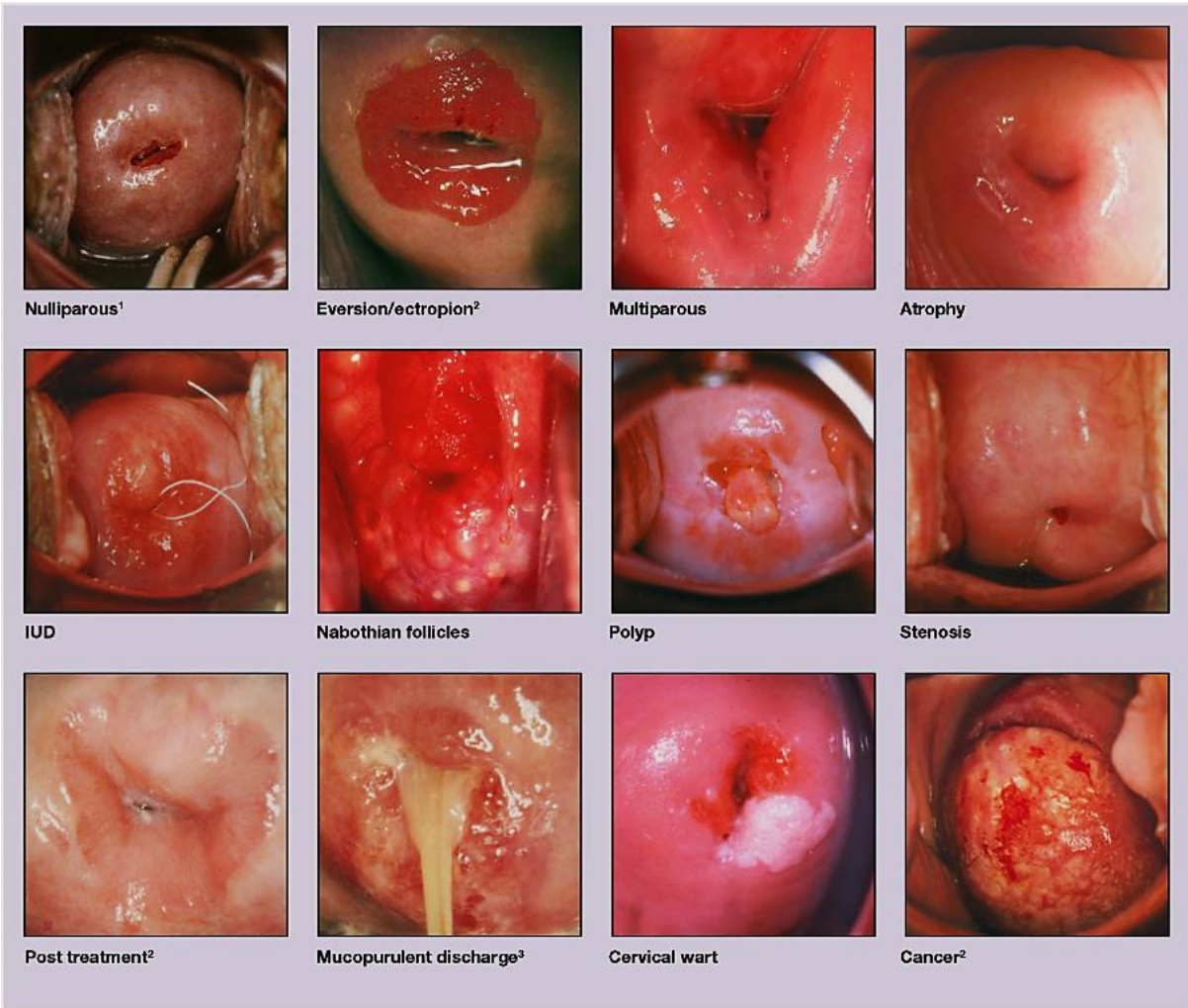


Inspection of the portio/cervix



[Cervix Photo Galleries | Beautiful Cervix Project](#)

Inspection of the portio/cervix



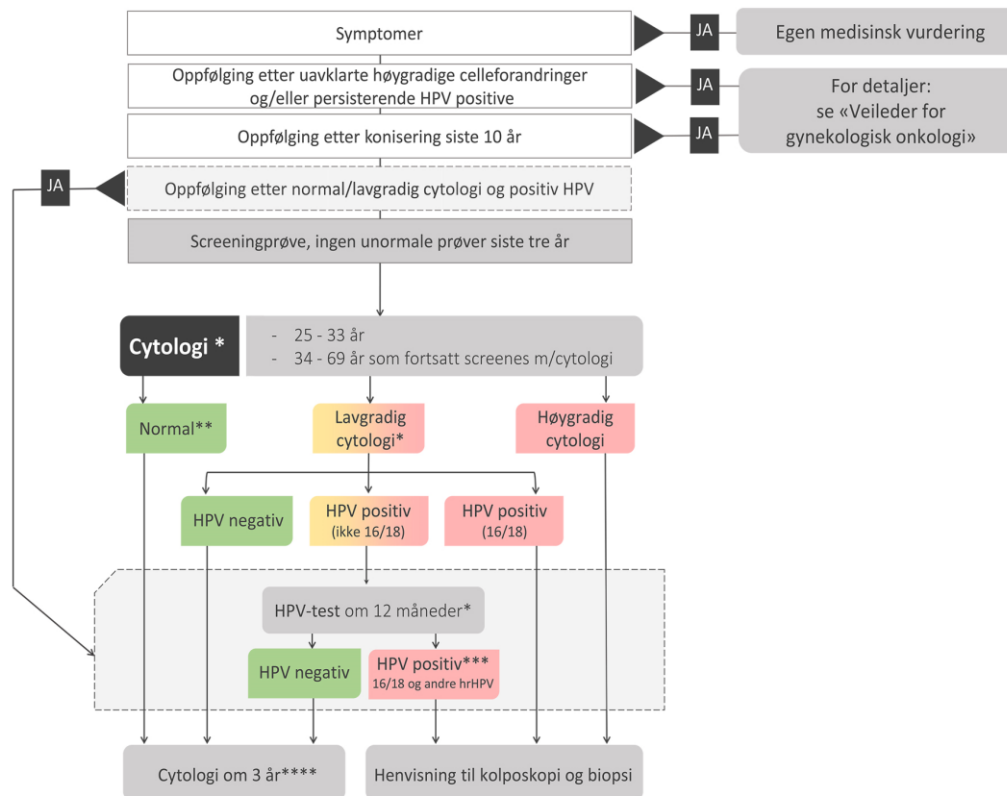
1 Reproduced with permission from: Wollenzake, Margaret, 1995. Taking Cervical Smears. British Society for Clinical Cytology; page 12.
 2 Reproduced with permission from: Burghardt, Erich, 1984. Colposcopy Cervical Pathology Textbook and Atlas. Georg Thiern Verlag. Germany; pages 162 & 174.
 3 Reproduced with permission from: Cartier, René, 1984. Practical Colposcopy. Laboratoire Cartier. Switzerland; page 168.

Flytskjema

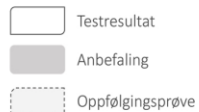for vurdering av
væskebaserte livmorhalsprøver

Hvorfor er livmorhalsprøven tatt?

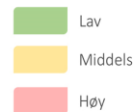
Prøvetaker må fylle ut årsak til prøve og opplysninger relevante for vurdering av prøven.



Figur- og begrepsforklaring



Risiko for alvorlige celleforandringer (CIN2+)



Fotnoter

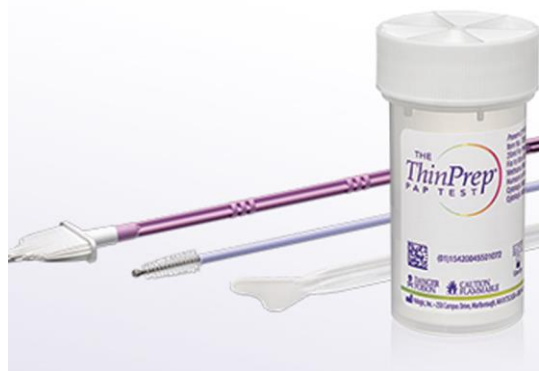- * Ved uegnet prøve (primær eller refleks), ny prøve innen 1-3 måneder. Ved uegnet cytologi andre gang, gjøres refleks-HPV.
- ** For kvinner over 34 år uten tidligere livmorhalsprøver, anbefales det å gjøre cytologi og HPV-test ved første livmorhalsprøve.
- *** For HPV positive prøver skal cytologi utføres, men prøvesvar vil ikke påvirke oppfølging. Resultatet brukes av gynekolog ved kolposkopisk undersøkelse.
- **** Ny HPV-test om 3 år dersom kvinnen ved tidspunkt for ny prøve er fylt 34 år og regionen har implementert HPV-screening i stedet for cytologi.

Lavgradig cytologi ASCUS (irregulær plateepitelceller med forandringer av usikker betydning)
LSIL (lavgradig skvamøs intraepitel lesjon)

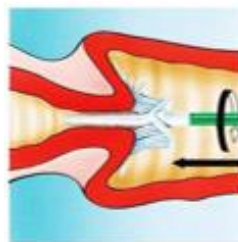
Høygradig cytologi ASC-H (irregulære plateepitelceller med forandringer som kan gi mistanke om høygradig lesjon, men som ikke fyller kriteriene til diagnosen HSIL)
HSIL (høygradig skvamøs intraepitel lesjon)
AGUS (irregulært sylindrer/kjertelepitel av usikker opprinnelse og/eller signifikans)
ACIS (adenokarsinoma in situ)

Unormal cytologi Lavgradig eller høygradig cytologi
hrHPV Høyrisiko humant papillomavirus
16/18 Genotype HPV16 og/eller HPV18

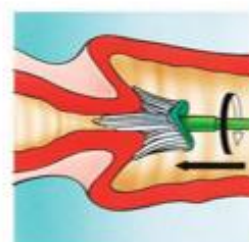
Cervical cytology – Liquid based tests



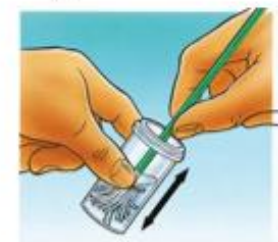Prøvetaking med kombinasjonsbørste type 1 eller type 2



Drei børsten **10** omdreininger

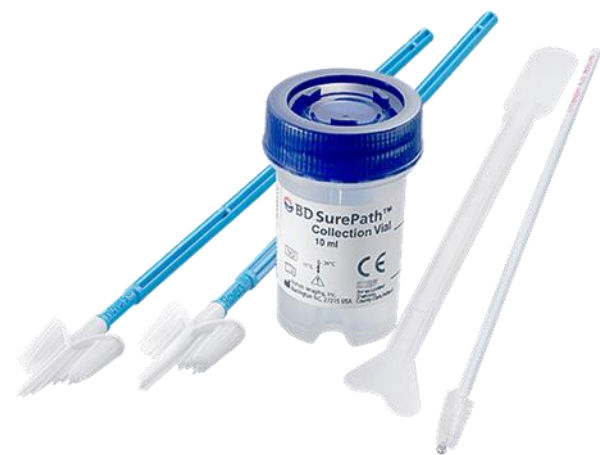

Drei børsten **FEM** omdreininger



Overføring av celled materiale til **ThinPrep** prøvebeholder

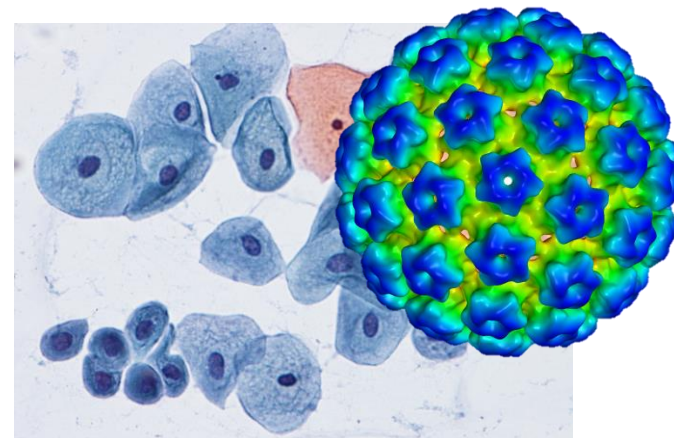
Stapp børsten umiddelbart 10 ganger i bunnen. Roter tilslutt børsten i væsken. Kast deretter børsten



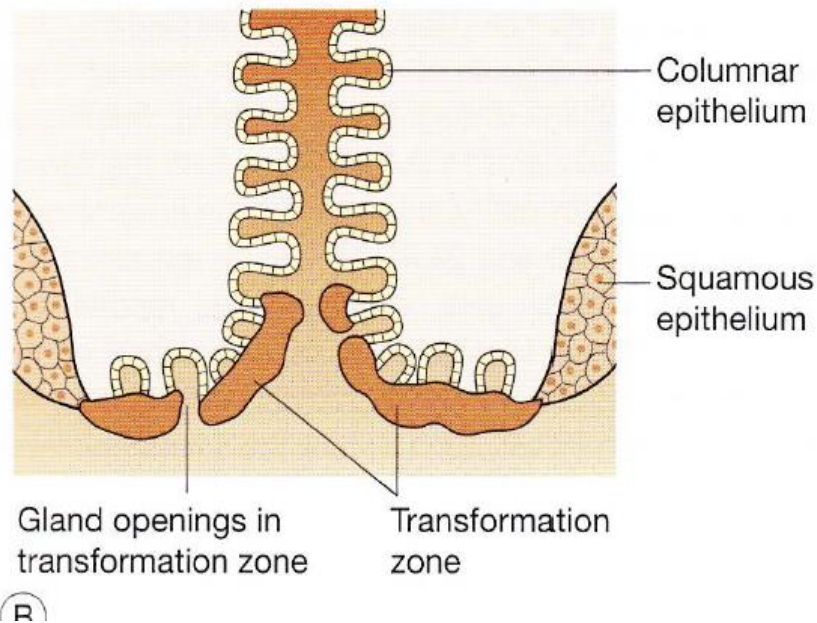
Overføring av celled materiale til **SurePath** prøvebeholder



Børstehodet hektes av ved hjelp av den blå kanten i prøvebeholder. Børstehodet skal bli liggende i det største kammeret



Inspection of the Transformation zone



ENDOCERVIX

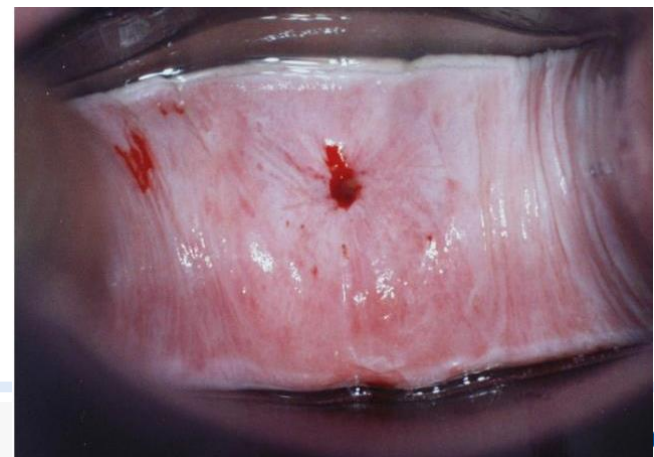
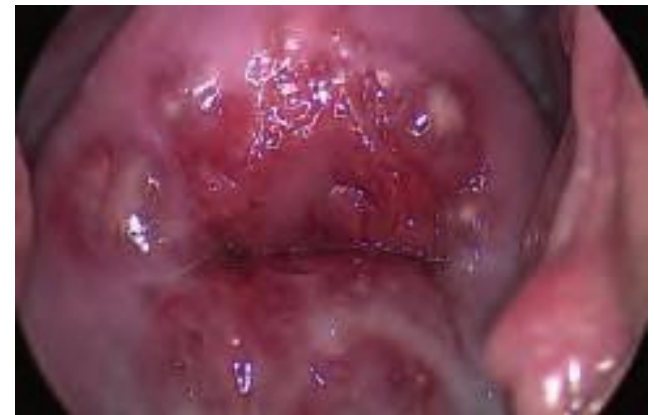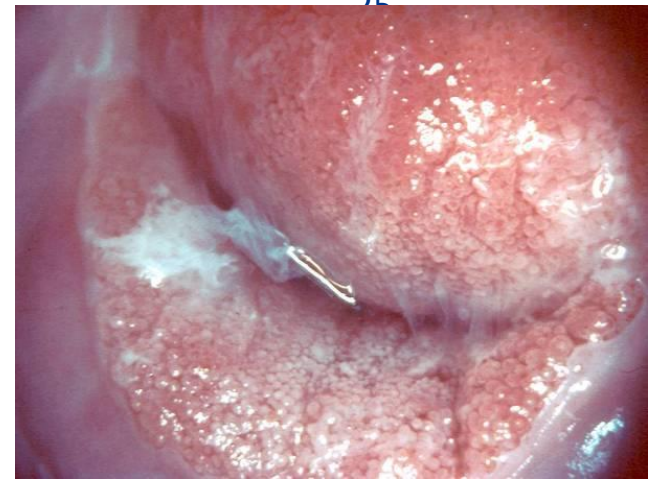
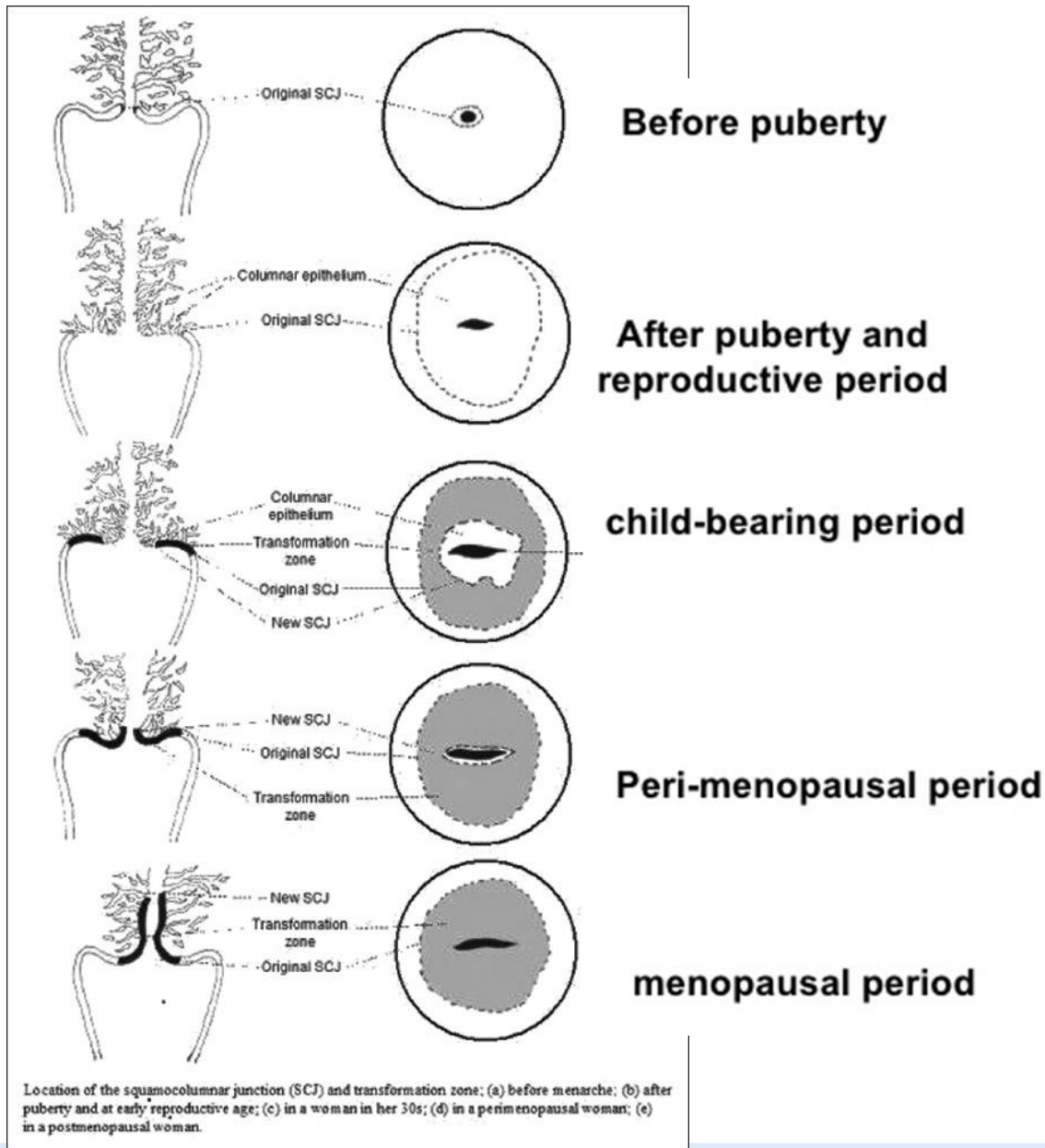
columnar epithelium

ECTOCERVIX

Stratified squamous epithelium

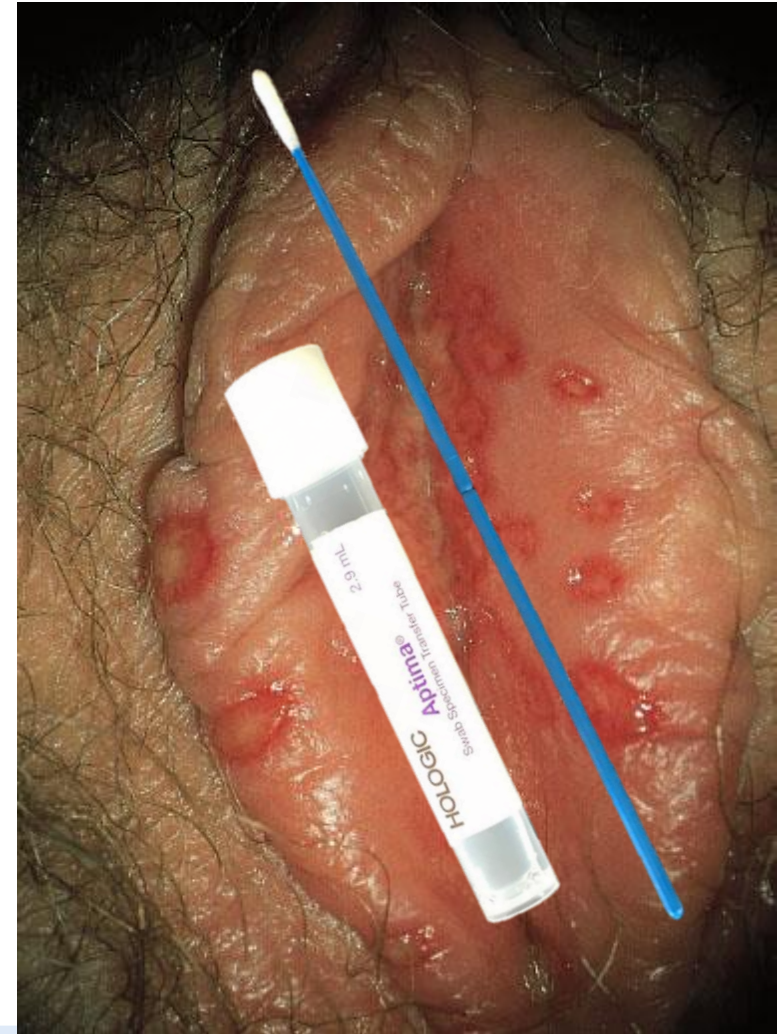
Meet at the squamocolumnar junction (SCJ)

Transformation zone- between original and new SCJ

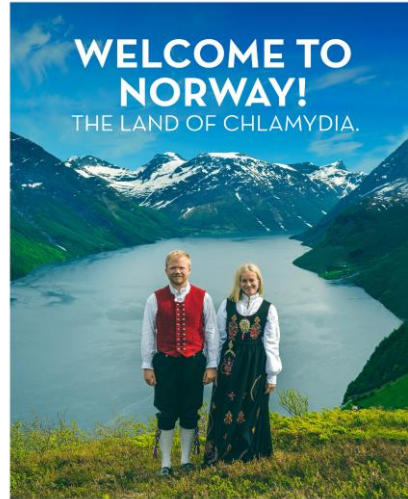
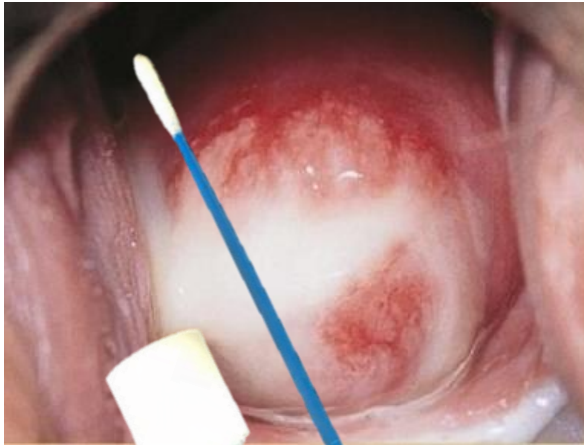

Microbiological tests – virus

- HPV
 - Liquidbased cytology
- HSV
 - NAAT
 - “fresh” lesion

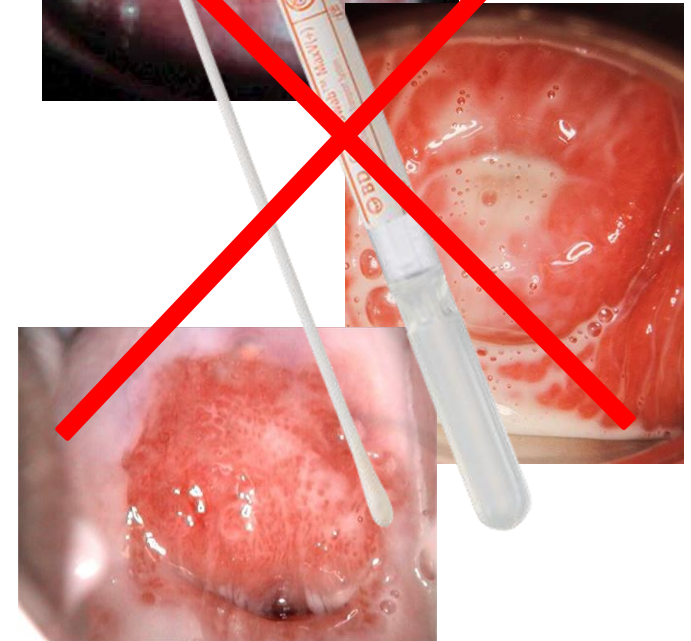
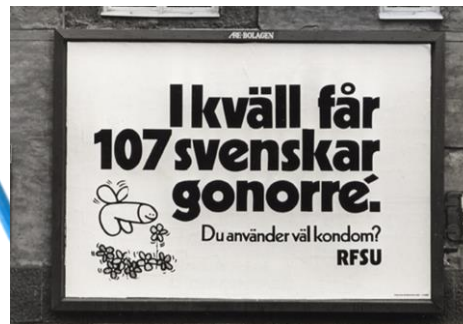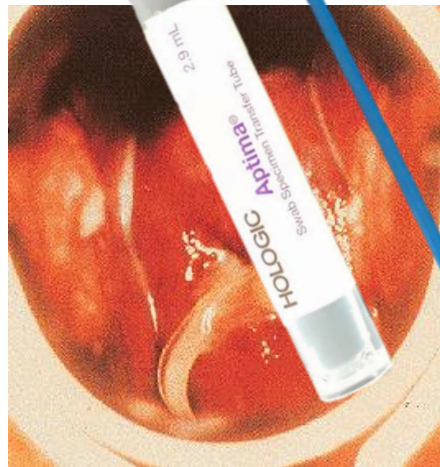

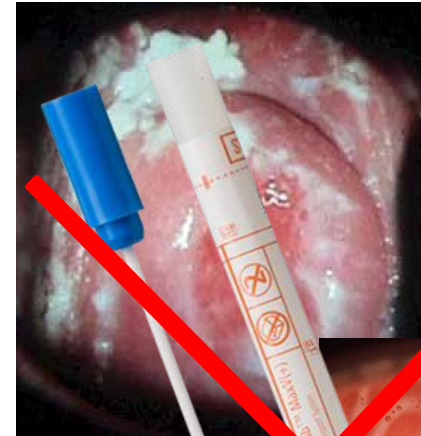
Microbiological tests

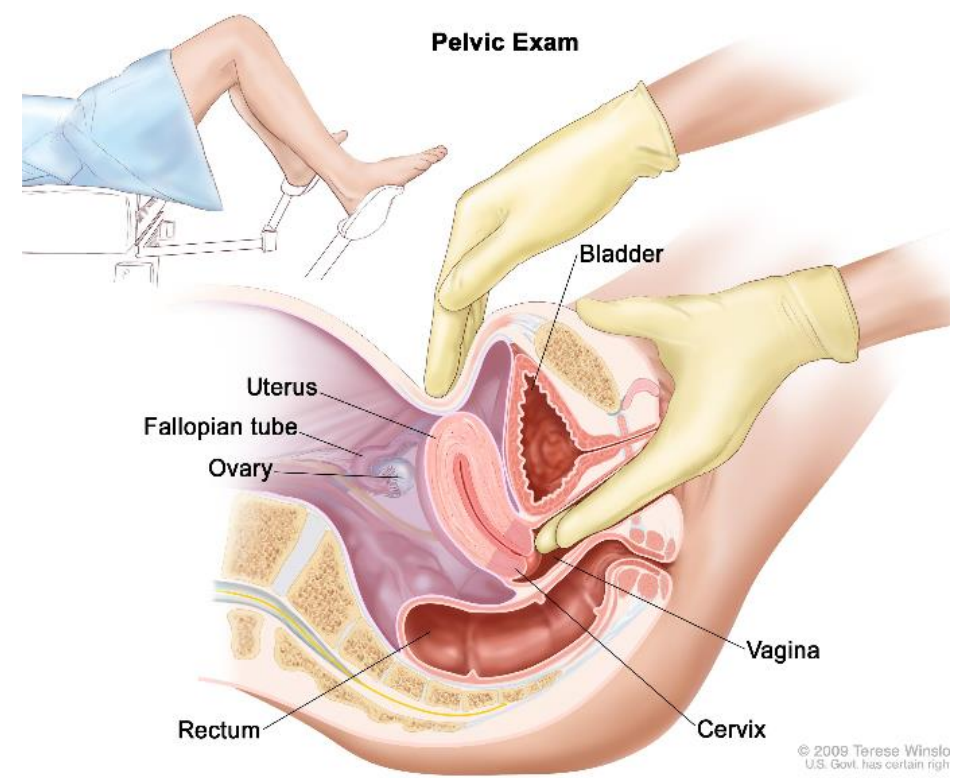


Norway has one of the highest rates of chlamydia in Europe. Visiting from abroad? Make sure to protect yourself against the locals! Get your condoms at the nearest 7-Eleven.

7-ELEVEN.



Bimanual palpation of the uterus



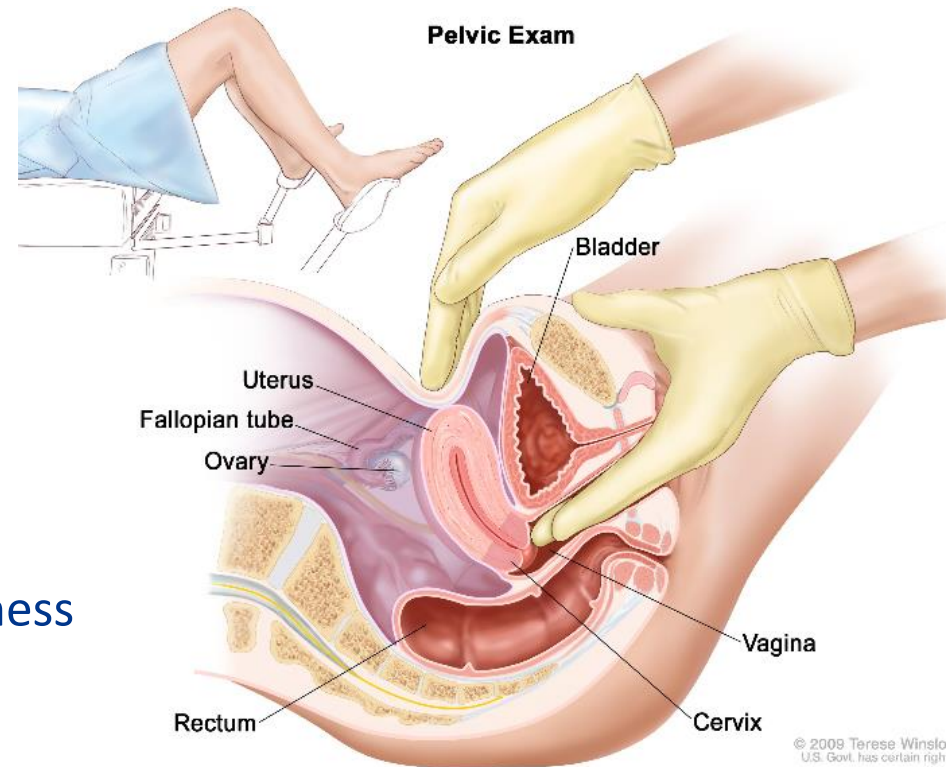
Use Lubricant

Bimanual palpation of the uterus

OUTLINE

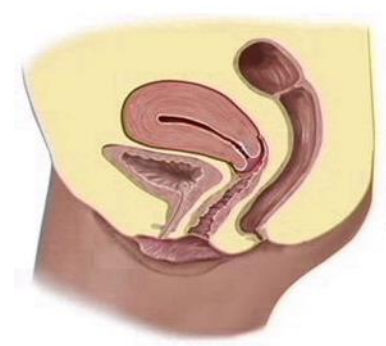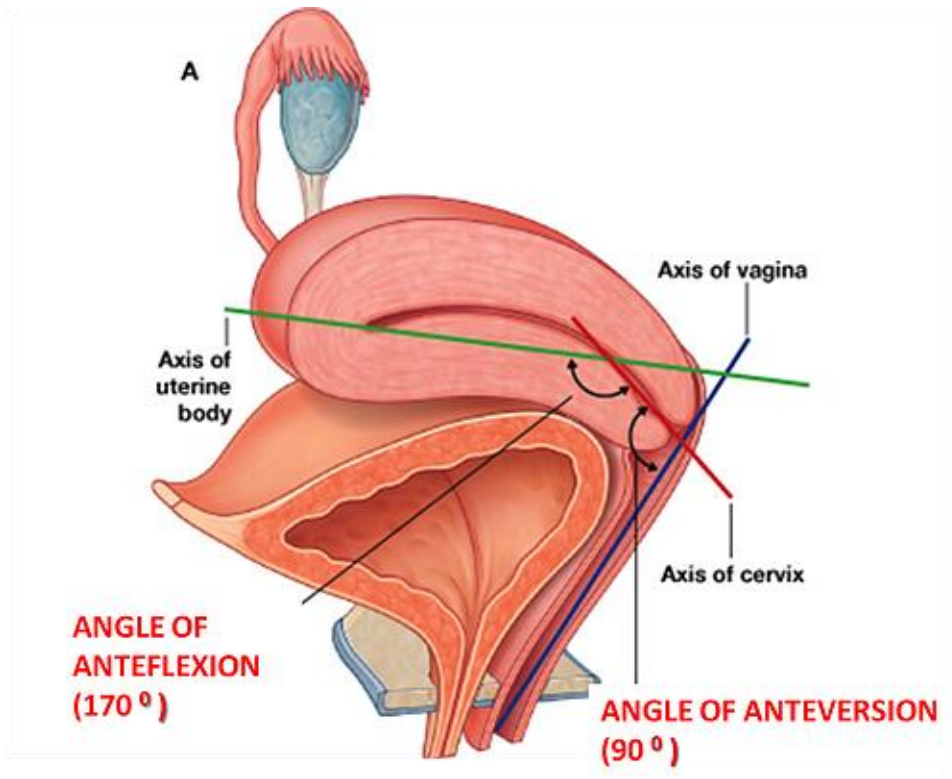
- Position
- Size and Shape
- Mobility
- Surface
- Consistency
- Tenderness

- CMT - cervical motion tenderness
«ruggeømheth»

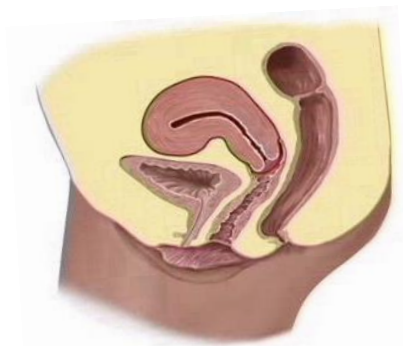

Bimanual palpation of the uterus

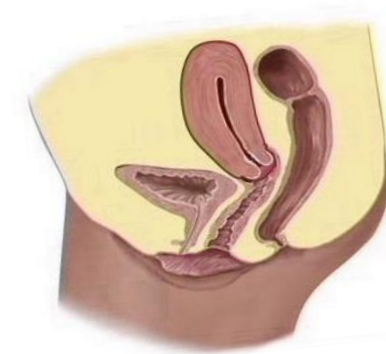- Position



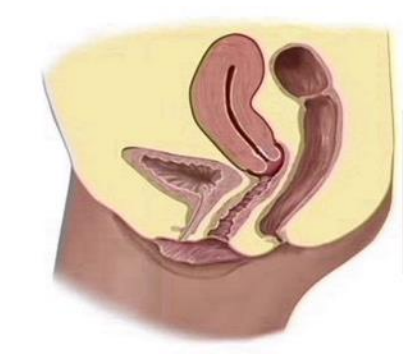
Anteverted



Anteflexed



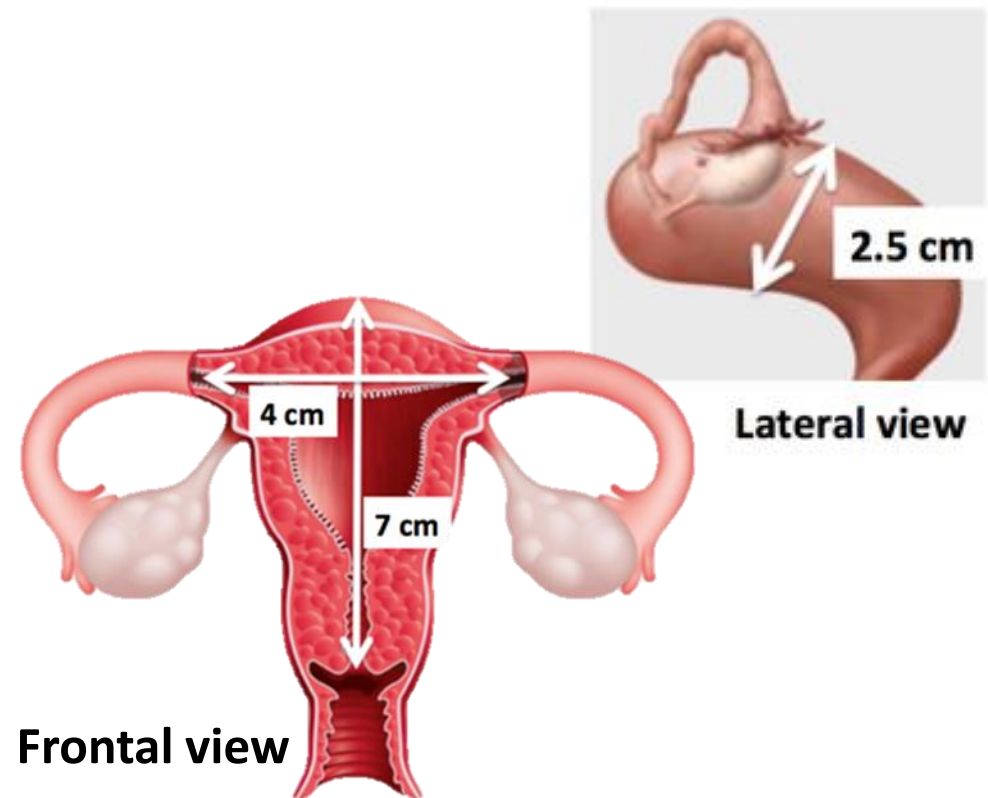
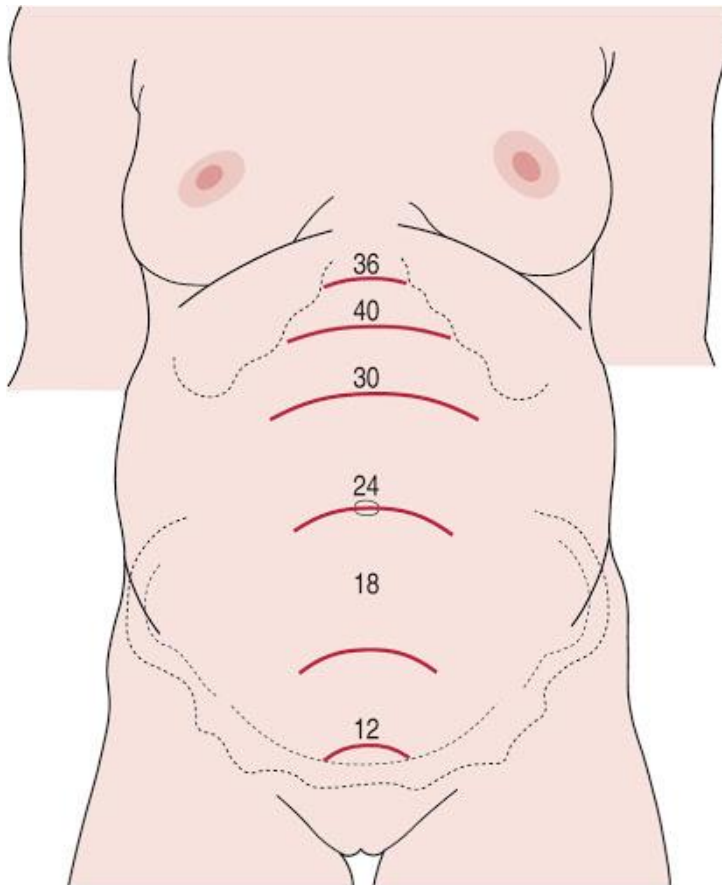
Retroverted



Retroflexed

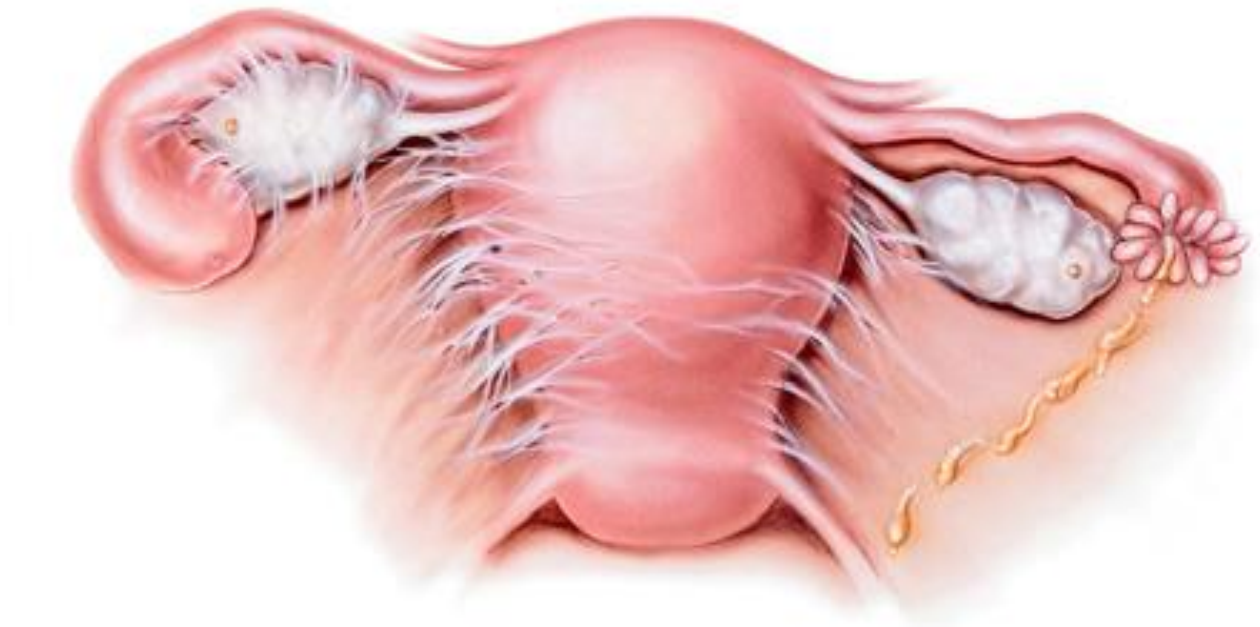Bimanual palpation of the uterus

- Size in relation to landmarks
- Size assessed with ultrasound

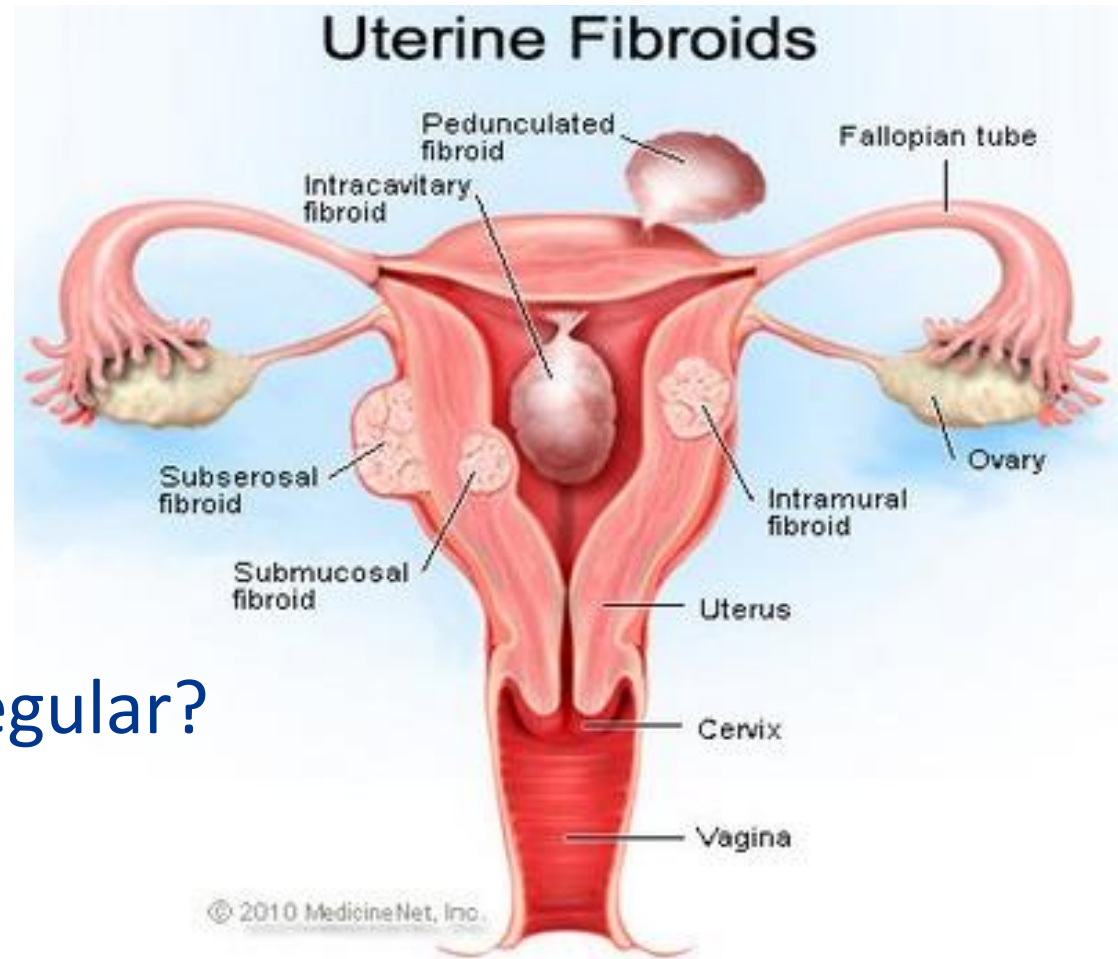


Bimanual palpation of the uterus

- Mobility



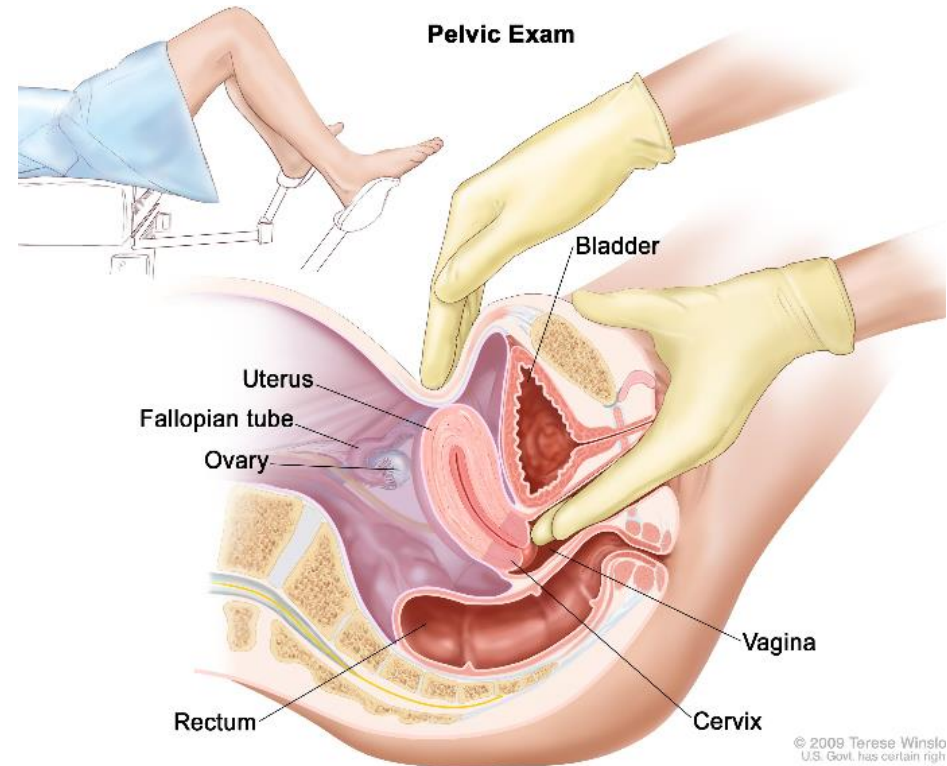
Bimanual palpation of the uterus



- Surface
 - smooth? irregular?
- Consistency

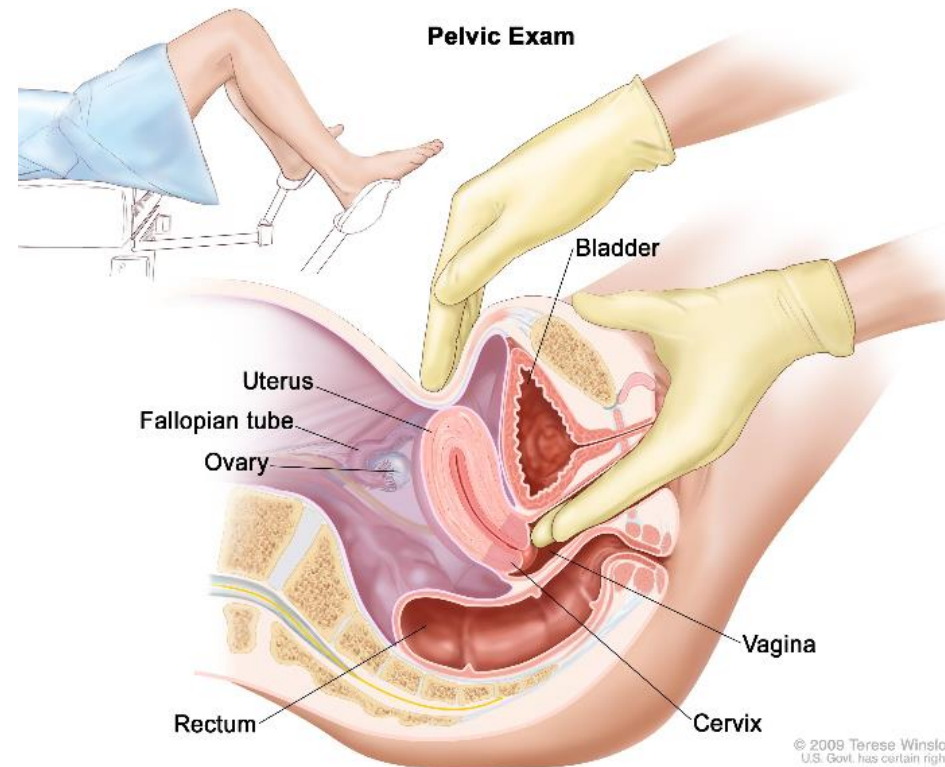
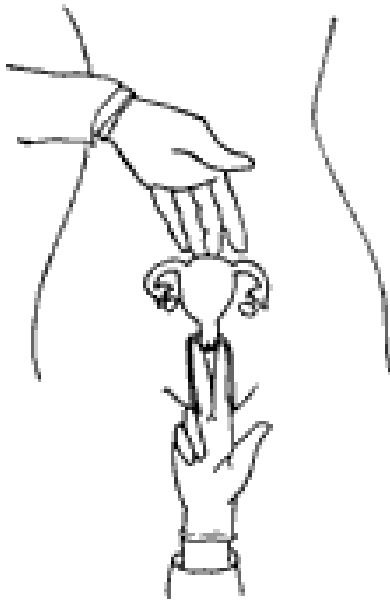Bimanual palpation of the uterus

- Tenderness



Bimanual palpation of the uterus

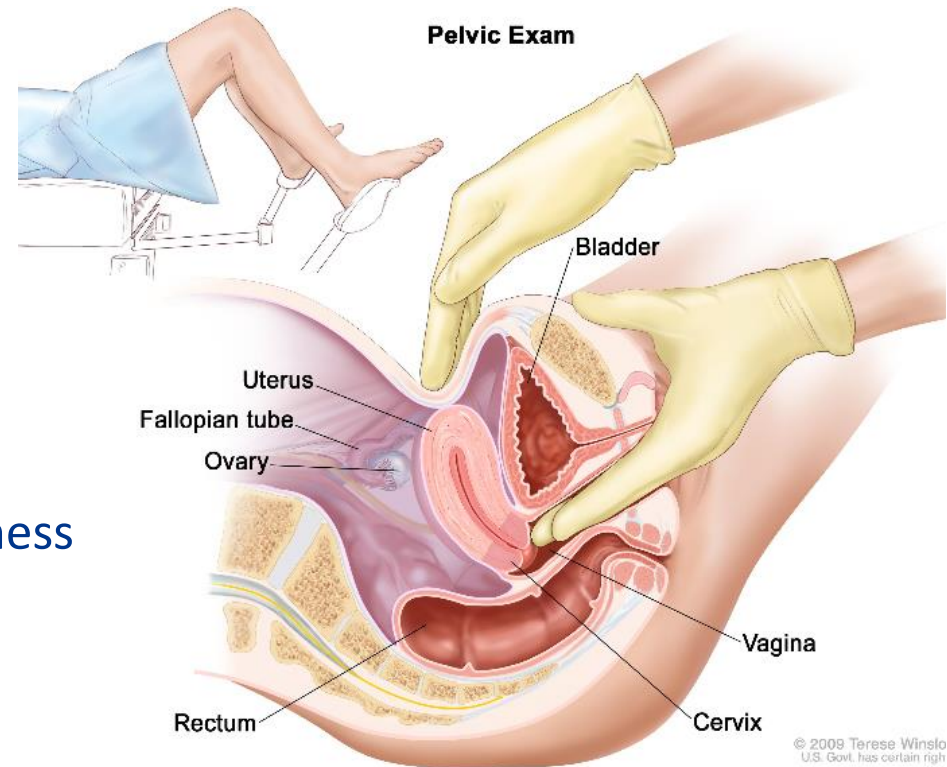
- CMT – cervical motion tenderness (no: ruggeømhhet)



Bimanual palpation of the uterus

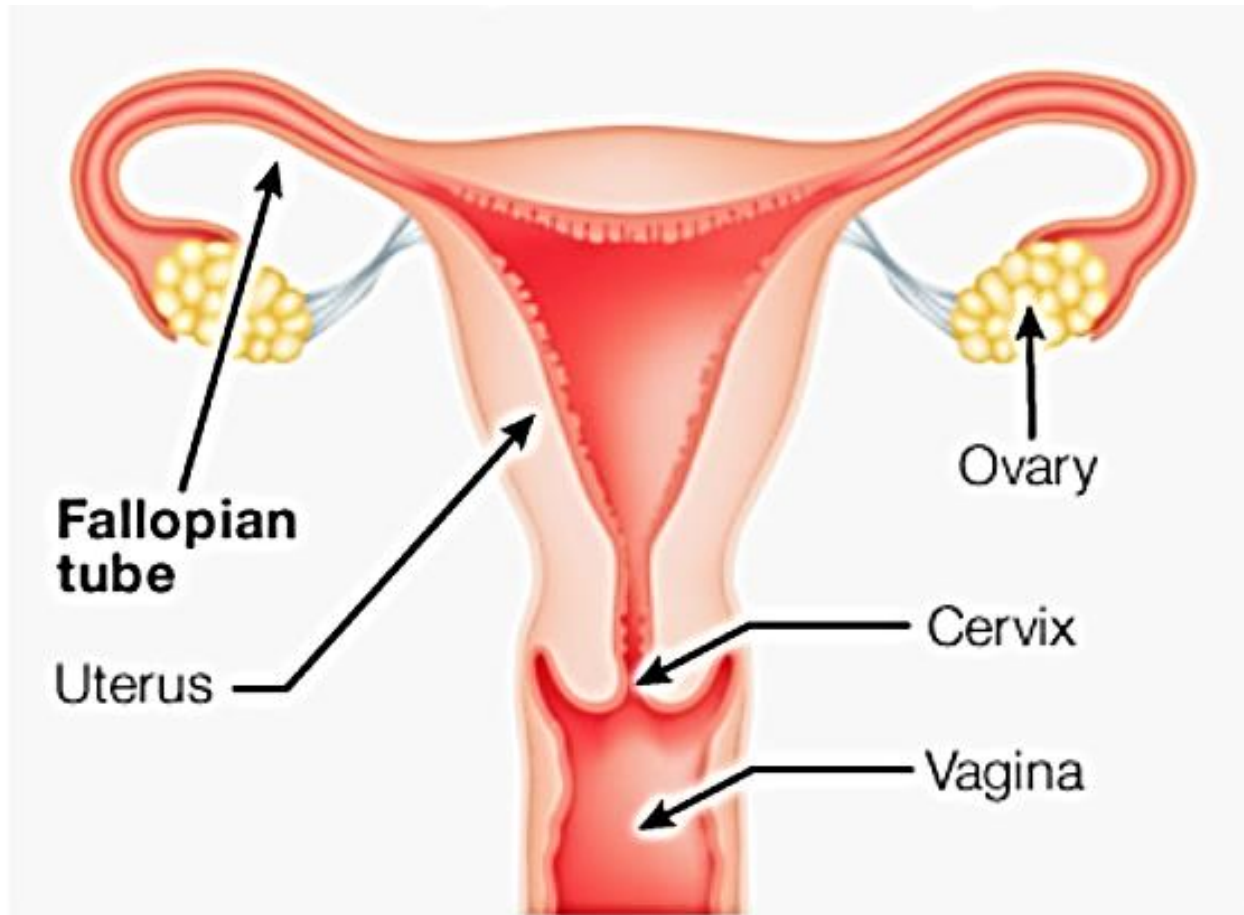
- Position
- Size and Shape
- Mobility
- Surface
- Consistency
- Tenderness

- CMT - cervical motion tenderness
«ruggeømheth»

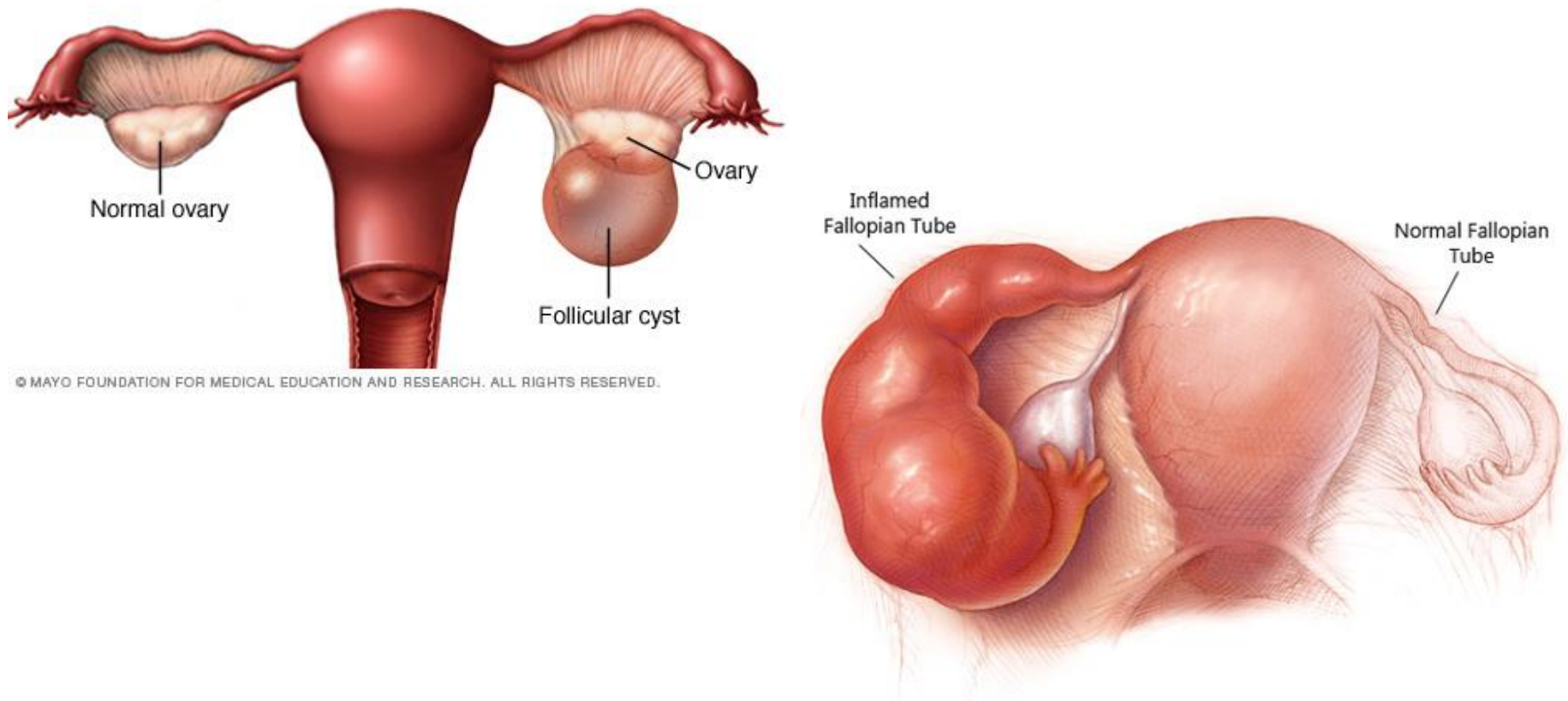


The adnexae

= fallopian tube AND the ovary



Examples of pathology of the adnexa



- <http://meddev.uio.no/elaring/fag/obstgyn/index.shtml#>